

In collaboration with the American College of Veterinary Surgeons

Navicular Syndrome in Equine Patients: Anatomy, Causes, and Diagnosis*

R. Wayne Waguespack, DVM, MS, DACVS**R. Reid Hanson, DVM, DACVS, DACVECC**

Auburn University

Abstract: Navicular syndrome is a chronic and often progressive disease affecting the navicular bone and bursa, deep digital flexor tendon (DDFT), and associated soft tissue structures composing the navicular apparatus. This syndrome has long been considered one of the most common causes of forelimb lameness in horses. Diagnosis of navicular syndrome is based on history, physical examination, lameness examination, and peripheral and/or intraarticular diagnostic anesthesia. Several imaging techniques (e.g., radiography, ultrasonography, nuclear scintigraphy, thermography, computed tomography [CT], magnetic resonance imaging [MRI]) are used to identify pathologic alterations associated with navicular syndrome. Radiographic changes of the navicular bone are not pathognomonic for navicular syndrome. Additionally, not all horses with clinical signs of navicular syndrome have radiographic changes associated with the navicular bone. Therefore, newer imaging modalities, including CT and especially MRI, can play an important role in identifying lesions that were not observed on radiographs. Navicular bursoscopy may be necessary if the clinical findings suggest that lameness originates from the navicular region of the foot and if other imaging modalities are nondiagnostic. With new diagnostic imaging techniques, clinicians are learning that anatomic structures other than the navicular bursa, navicular bone, and DDFT may play an important role in navicular syndrome.

Navicular syndrome is chronic and often progressive, affecting the navicular bone and bursa as well as the associated deep digital flexor tendon (DDFT) and soft tissue structures composing the navicular apparatus.¹ Navicular syndrome has long been considered one of the most common causes of forelimb lameness in horses. As early as 1752, it was recognized that changes in the distal sesamoid bone (navicular bone) correlated with clinical lameness.² In one study, navicular syndrome was found to be responsible for approximately one-third of cases of chronic lameness affecting horses.³ This syndrome is responsible for loss of function in many equine athletes. Although this syndrome has been present for centuries, considerable controversy regarding its pathogenesis, diagnosis, and treatment persists. This article reviews the anatomy of the navicular region and the pathogenesis and diagnosis of navicular syndrome.

Anatomy of the Equine Digit

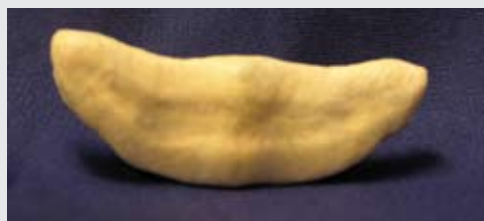The navicular bone is boat shaped and lies at the palmar aspect of the distal interphalangeal joint (DIPJ; **FIGURE 1**). The bone develops by endochondral ossification from a single center of ossification⁴ and is completely ossified by approximately day 325 of gestation. Dorsally, its articular surface, which is covered with hyaline cartilage, articulates with the distal-palmar aspect of the middle phalanx. The palmar flexor surface is characterized by a prominent sagittal ridge and is covered by fibrocartilage, providing a smooth surface on which the apposing DDFT can glide during loading of the limb. The distal border contains a small articular facet of hyaline cartilage for articulation with the distal phalanx.⁵ In addition, the distal border contains numerous foramina lined with synovium.^{4,6}

Three ligaments support the navicular bone. A pair of collateral sesamoidean ligaments arises from depressions on either side of the distal end of the proximal phalanx. They extend in a distal-palmar direction to insert on the extrem-

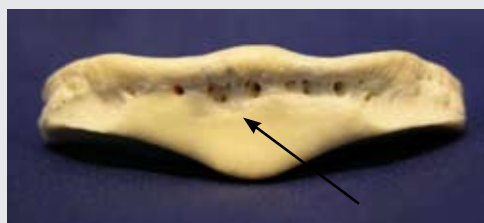*Watch for an upcoming companion article titled "Treating Navicular Syndrome in Equine Patients."

FIGURE 1

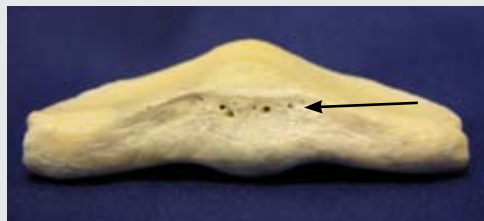The navicular bone.



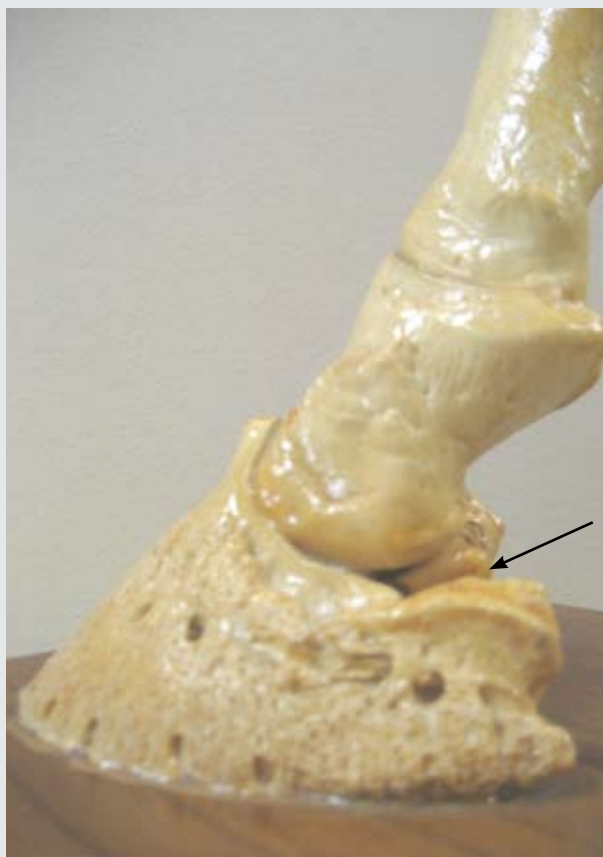The navicular bone, or distal sesamoid bone, which is boat shaped.



The distal aspect of the navicular bone and the associated synovial fossae (arrow).



The proximal aspect of the navicular bone and the associated foramina (arrow).



The normal anatomic position of the navicular bone (arrow).



ACVS
AMERICAN COLLEGE of
VETERINARY SURGEONS

Surgical Views is a collaborative series between the American College of Veterinary Surgeons (ACVS) and *Compendium*.

All Surgical Views articles are peer-reviewed by ACVS diplomates.

To locate a diplomate, ACVS has an online directory that includes practice setting, species emphasis, and research interests (acvs.org/VeterinaryProfessionals/FindaSurgeon).

ities and proximal border of the navicular bone, thereby “suspending” the navicular bone.^{7,8} A branch from each collateral sesamoidean ligament originates at the palmar process (angle) of the distal phalanx and inserts on the axial surface of the ipsilateral cartilage of the foot.⁸ The distal sesamoidean impar ligament originates from the distal margin of the navicular bone, extending to the flexor surface of the distal phalanx and inserting deep to the DDFT.⁷

The synovial structures associated with the navicular bone are somewhat complex (**FIGURE 2**). The navicular bursa is located between the flexor surface of the navicular bone and the DDFT. It extends proximally 1 to 1.5 cm from the navicular bone and distally to the insertion of the DDFT on the distal phalanx.⁹ Several studies using positive-contrast radiography have confirmed that no direct anatomic communication exists between the navicular bursa and the DIPJ.^{10,11} The DIPJ is a complex synovial structure near the navicular bone. It consists of dorsal and palmar extensions

along the respective surfaces of the middle phalanx, with a small additional recess between the navicular bone and the distal phalanx.¹²

Sensory innervation to the navicular bone is supplied by the digital nerves.⁷ Nerve fibers run distally through the collateral sesamoidean ligaments and are present within the distal sesamoidean impar ligament.¹³ Innervation to the synovial structures (i.e., the navicular bursa and the DIPJ) has been the subject of recent studies.^{14,15} The digital nerves supply sensory innervation to these structures; however, there is considerable controversy over the possibility of an indirect, functional communication between the DIPJ and the navicular bursa, which may confuse intrasynovial anesthesia results.¹⁴

The arterial supply to the navicular bone is formed from an anastomosing network between the medial and lateral palmar digital arteries.^{7,16,17} Proximally, a transverse plexus joining the lateral and medial palmar digital arteries gives rise to several small arteries that enter foramina of the navicular bone along its proximal border. Distally, branches connecting the medial and lateral palmar digital arteries form a distal navicular plexus, which gives off additional small arteries that enter foramina along the distal border. These distal arteries supply most of the blood to the navicular bone. Anastomoses between the proximal and distal blood supply have been demonstrated in adult horses. Venous drainage occurs via the medial and lateral palmar digital veins.

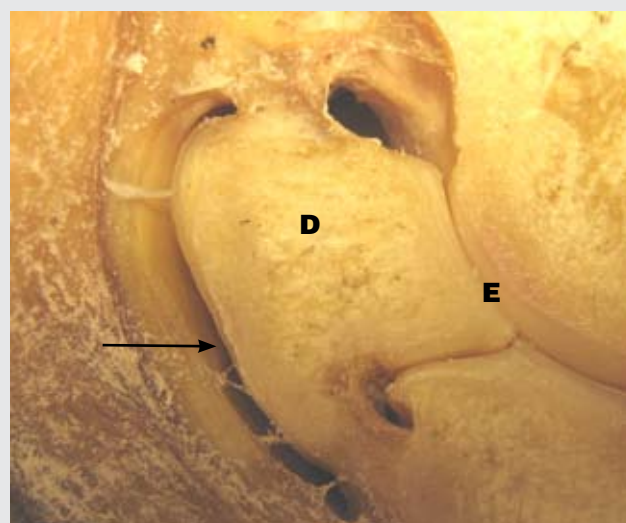
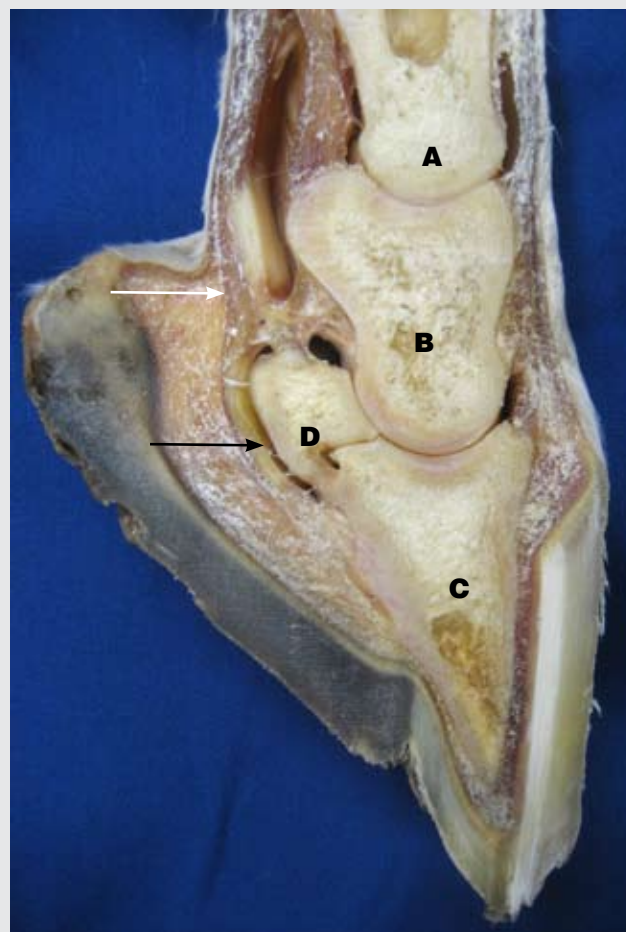
Biomechanical Considerations

The primary function of the navicular bone is to provide a constant angle of insertion for the DDFT.¹⁸ Alignment of the trabecula (i.e., Wolf's law states that the trabecula will align in the direction of stress) within the cancellous bone of the navicular bone suggests that the principal force experienced by the navicular bone is compression by the DDFT.¹⁹ The forces acting on the navicular bone include forward compression by the DDFT, compressive forces downward from the middle phalanx, and tension from the suspensory apparatus of the navicular bone.²⁰ The relative contribution of each of these forces varies from horse to horse, depending on factors such as conformation and weight.

Pathogenesis

Three major theories regarding the pathogenesis of navicular syndrome have evolved.²¹ The first one proposes a vascular etiology. This theory, supported by Colles,²² cites thrombosis of the arterioles supplying the distal aspect of the navicular bone, causing pain and ischemic necrosis of the bone. Others^{23,24} have found evidence of hyperemia (increased vascularity) rather than ischemia in navicular bones from clinically affected horses.

FIGURE 2



Midsagittal section of a gross anatomic specimen of the distal phalanges: first phalanx (A), middle phalanx (B), distal phalanx (C), navicular bone (D), distal interphalangeal joint (E), deep digital flexor tendon (white arrow), navicular bursa (black arrows).

Critical Points

- Navicular syndrome is a chronic and often progressive disease affecting the navicular bone, navicular bursa, deep digital flexor tendon, and associated soft tissue structures composing the navicular apparatus. This syndrome has long been considered one of the most common causes of forelimb lameness in horses.
- The specific pathogenesis of navicular syndrome is unknown, but three possible etiologies have been proposed: vascular alterations, chronic inflammation, and repetitive biomechanical forces.
- Diagnosis of navicular syndrome is based on history, physical examination, lameness examination, peripheral and/or intraarticular diagnostic anesthesia, and imaging techniques, including radiography, ultrasonography, nuclear scintigraphy, thermography, CT, and MRI. Navicular bursoscopy may be necessary when other imaging modalities are nondiagnostic if the clinical findings suggest that the lameness originates from the navicular region of the foot.
- The primary function of the navicular bone is to provide a constant angle of insertion for the deep digital flexor tendon.
- Numerous researchers have demonstrated that changes in the fibrocartilage of the flexor surface of the navicular bone, subchondral bone, medullary cavity, and bursal synovium are similar to changes observed in the hyaline cartilage and synovial membranes of joints with osteoarthritis.
- Lameness is exacerbated by hard surfaces and trotting in tight circles (typically, when the lame leg is on the inside).
- Radiography is the most common modality for supporting a clinical diagnosis of navicular syndrome. To fully evaluate the navicular bone, five views are recommended.
- After removal of the shoes, adequate preparation of the hoof is imperative for obtaining high-quality radiographs. Radiographic artifacts associated with air accumulation within the crevices of the frog appear as lucencies on radiographs and can mimic fracture lines or cyst-like lesions on the navicular bone. To prevent these artifacts by eliminating air pockets, the hoof should be well packed with a compound that has radiographic soft tissue density (e.g., Play-Doh) or should be placed in a plastic container filled with water (the cassette is placed beneath the container).
- Compared with radiography, scintigraphy is much more sensitive for detecting bony lesions; at least 50% of a bone's mineral content must be lost before lysis can be visualized by radiography.

The second theory involves biomechanical causes. Thompson et al²⁵ suggested that continual pressure between the DDFT and the flexor surface of the navicular bone leads to degenerative changes of these structures. Other investigators²⁶ have shown that structural changes within the distal sesamoid bone were due to remodeling of the spongiosa underlying the flexor fibrocartilage in response to increased pressure between the DDFT and the flexor surface of the navicular bone. Additionally, factors such as upright conformation, small hoof size, poor shoeing technique (short heel and long toe), and large body size were considered to contribute to this syndrome.²⁷

The third and most accepted theory suggests that navicular syndrome is a process similar to osteoarthritis (degenerative joint disease). Numerous researchers^{21,23,28–32} have demonstrated that changes in the fibrocartilage of the flexor surface of the navicular bone, subchondral bone, medullary cavity, and bursal synovium are similar to changes observed in the hyaline cartilage and synovial membranes of joints with osteoarthritis.^{28,32} Additionally, surface fraying of the

DDFT, core lesions, and adhesions between the navicular bone and the DDFT have been observed.^{21,28,32}

Evaluation of these theories supports a mechanical cause of navicular syndrome that involves either abnormal loads applied to normal structures or abnormal structures subjected to normal loads. Either cause leads to an imbalance between applied forces and the tissues' ability to compensate and withstand the loads.²⁰ The various theories of etiology reflect, in part, the lack of understanding of the temporal relationship of the pathologic changes found in the navicular bone and its surrounding structures.

Diagnosis

Navicular syndrome can affect horses of many breeds and ages. In North America, Quarter horses and Thoroughbreds have a higher incidence than other breeds.³³ Geldings also appear to be overrepresented.³³ Whether these are true breed and sex predilections is unclear; these findings may be related to the workload of the horses in this study. Affected horses are typically 4 to 15 years of age. A hereditary compo-

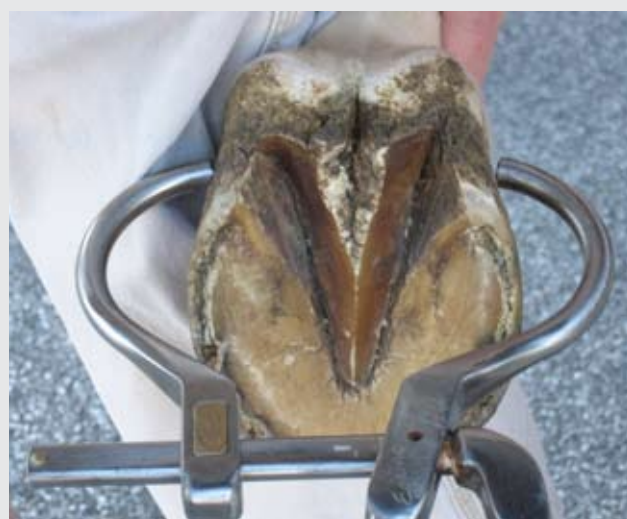nent of navicular syndrome has been investigated; however, this may be related to certain conformational factors.³⁴

Horses with navicular syndrome often present with a history of forelimb lameness of insidious onset—often mild at first, with the lameness resolving with work. In time, the lameness may become exacerbated by exercise. The gait is often characterized by short, choppy strides, and the lameness is usually bilateral, with one limb more predominant than the other. Hard surfaces and trotting tight circles (which typically worsens the lameness when the lame leg is on the inside) also exacerbate the lameness. Severely affected horses may demonstrate a characteristic stance at rest, pointing the affected forelimb(s). Although hoof capsule shape can change in many cases of chronic lameness, longstanding cases of navicular syndrome may involve alterations in hoof conformation, including a small, narrow hoof with high heels.¹

Horses with navicular syndrome often show a pain response (i.e., limb withdrawal) to pressure applied with hoof testers over the middle one-third of the frog (FIGURE 3). To reduce the likelihood of false-positive results, it is important to compare the horse's pain response over the navicular region to the pain response in other regions on the same foot, in the opposite foot, and in the hind feet. False-negative results can occur with improper application of hoof testers, with the use of poor-quality hoof testers, or when inadequate pressure is achieved in feet with pads and/or thick, tough, keratinized frogs.

Regional perineural anesthesia of the palmar digital nerves is an important diagnostic tool for evaluating suspected cases of navicular syndrome. Careful technique must be used to ensure that the dorsal branches of the palmar digital nerves are not inadvertently included during injection and that only the palmar aspect of the hoof is anesthetized. One to 2 mL of 2% mepivacaine or lidocaine is administered perineurally at the level of the cartilage of the foot just proximal to the heel bulbs (FIGURE 4). Adequate anesthesia of the region, both cutaneous and deep, should be confirmed before evaluating the lameness. For confirmation, a blunted object (e.g., ballpoint pen cap, hoof pick) should be applied just proximal to the coronary band (both the dorsal and palmar aspects) and heel. Deep sensation in the navicular region, heel, and sole should be tested by reapplication of hoof testers approximately 5 to 10 minutes after injection. Frequently, the entire foot can become anesthetized after a palmar digital block. This usually results from inadvertent anesthesia of the dorsal branches of the palmar digital nerves due to inaccurate location of the palmar digital block or excessive use of local anesthetic and subsequent diffusion. Additionally, it must be recognized that deep sensation may persist although cutaneous sensa-

FIGURE 3

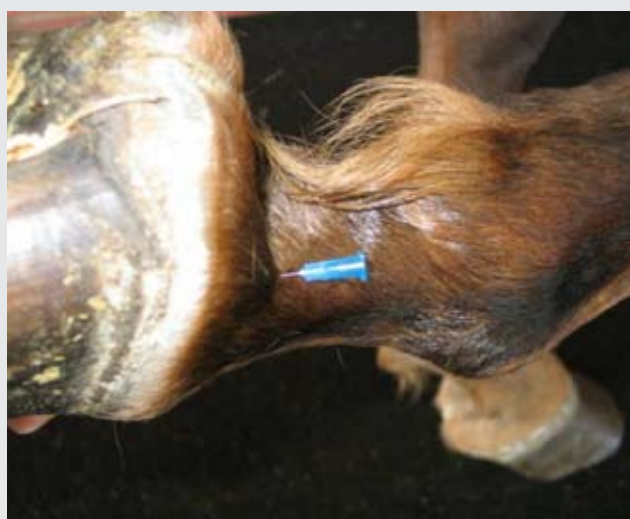


Most horses with navicular syndrome test positive on hoof-tester evaluation over the frog. As shown, the hoof testers are positioned to apply direct pressure on the frog. The horses are usually lame in both forelimbs, but lameness is usually more pronounced in one forelimb.

tion is lost. A probable explanation for this phenomenon is that variant nerve branches may escape anesthesia with routine palmar digital nerve blocks. With the possible variations in performing palmar digital nerve blocks, it is important to determine the area of desensitization.

After resolution of the lameness secondary to diagnostic anesthesia, unilaterally lame horses often exhibit a similar lameness in the contralateral limb. Horses with bilateral forelimb lameness usually show a dramatic improvement in gait after palmar digital nerve anesthesia of both forelimbs. Although useful in diagnosing navicular syndrome, palmar digital nerve blocks are not specific for navicular syndrome,

FIGURE 4

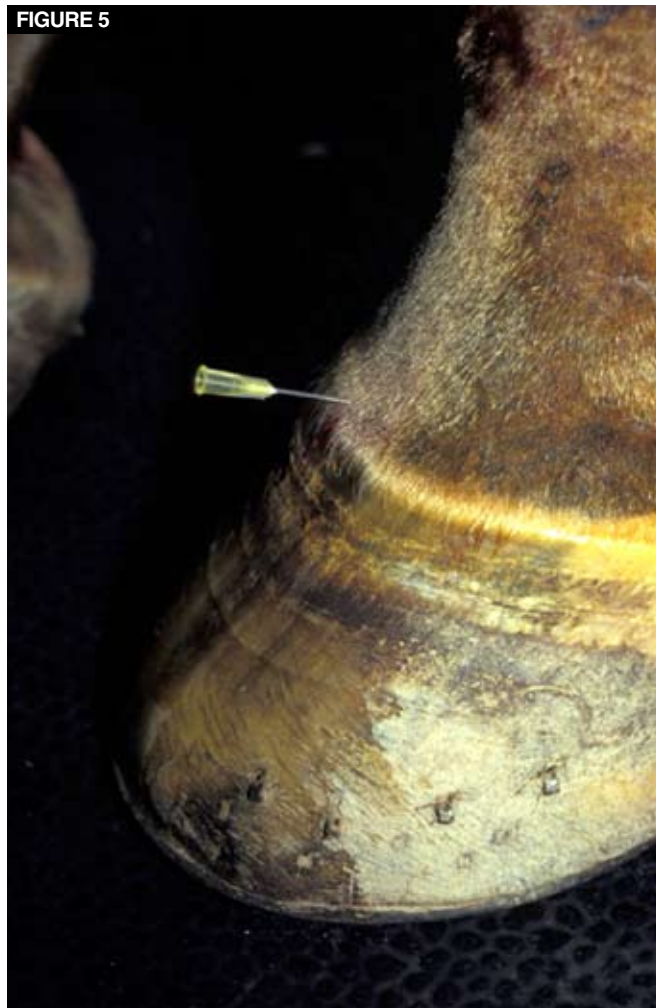

The recommended method of holding the lower limb and properly placing a needle for administering a lateral palmar digital nerve block. The needle is placed subcutaneously and directed over the lateral palmar digital nerve, just proximal to the collateral cartilages of the foot.

and horses with navicular syndrome may not always show significant improvement after blocking. This can be due to factors such as sole bruising, mechanical restrictions involving adhesions between the navicular bone and the DDFT, and accessory nerve supply to the region.¹ The results of regional anesthesia should be interpreted with the results of other clinical findings, such as those from the history, physical examination, and imaging.

Anesthesia of the synovial structures surrounding the navicular region has also been used in an attempt to localize pain in clinically affected horses.³⁵⁻³⁷ It is thought that injection of local anesthetic into the DIPJ (FIGURE 5) can

FIGURE 5



A common method of centesis of the distal interphalangeal joint. The hair can be clipped before sterile preparation, but this typically depends on the veterinarian's training. With the use of aseptic technique, a 1.5-inch, 20-gauge needle is inserted into the dorsal aspect of the joint 1 cm above the coronary band and directed parallel to the ground.

distinguish navicular pain from DIPJ pain; however, the specificity of this technique has recently been questioned. One group of investigators³⁵ demonstrated that a positive response to anesthesia of the DIPJ did not imply that pain arose solely from the joint; rather, the response could be associated with significant abnormalities (e.g., navicular bursitis, deep digital flexor tendonitis, impar ligament desmitis) of the navicular region. A negative response to anesthesia of the DIPJ did not preclude the presence of navicular bone pathology.³⁵ Additional studies support the theory that intraarticular anesthesia of the DIPJ is not specific for lameness originating from the DIPJ. In these studies, a positive response to intraarticular anesthesia of the DIPJ alleviated solar pain³⁸ and pain associated with the palmar processes

of the distal phalanx, the distal sesamoidean impar ligament, the DDFT, and the joint itself.^{35–37} To better interpret intraarticular anesthesia of the DIPJ, several studies have evaluated the specific volume to use and when to evaluate the response to this block.^{35,39,40} Intraarticular anesthesia of the DIPJ using 6 mL of mepivacaine can alleviate or improve pain associated with the navicular bone within 5 minutes of injection.^{35,39} Schumacher et al⁴⁰ showed that misleading results are more likely to occur with larger volumes of local anesthetic solution and with evaluation of the response more than 10 minutes after injection.

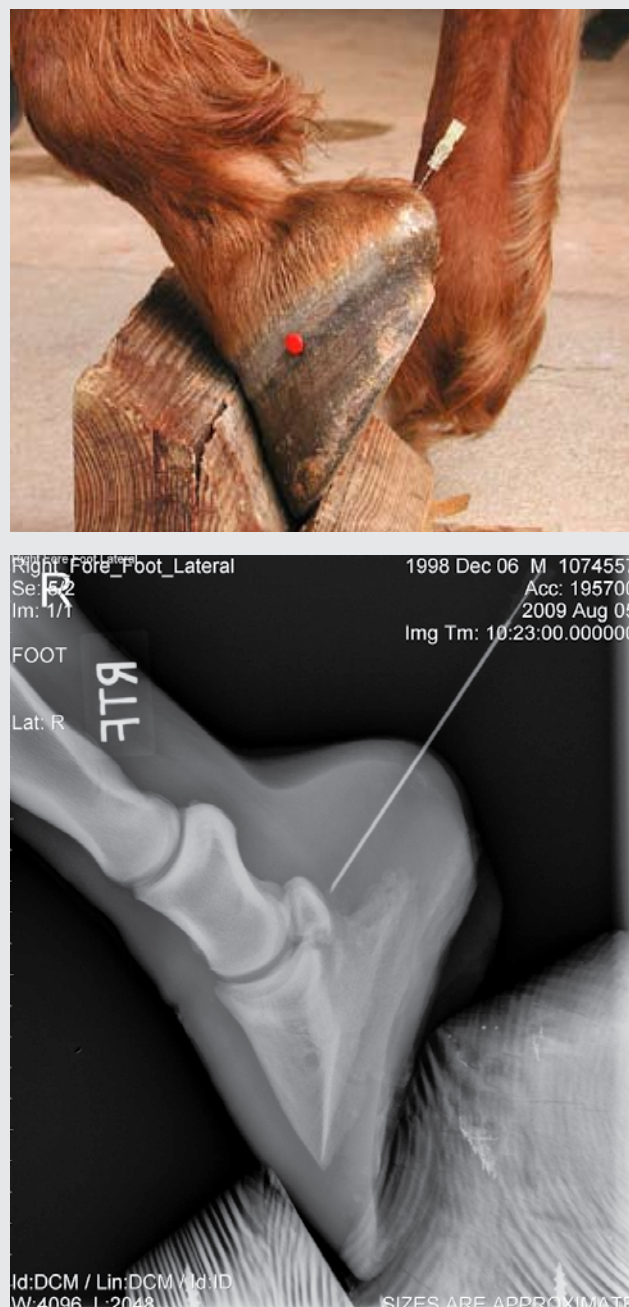
Intrabursal anesthesia (3 to 4 mL of 2% mepivacaine hydrochloride (Carbocaine-V, Pfizer Animal Health) of the navicular bursa has been recommended for the evaluation of navicular pain (**FIGURE 6**). Some researchers³⁹ believe this technique is useful only in distinguishing horses with true navicular bursitis. Improvement in lameness is usually appreciated within 5 minutes of injection of local anesthetic solution. A positive response to bursal anesthesia most likely indicates that pathology of the navicular bursa, bone, and/or supporting ligaments is the source of pain.³⁷ Interpretation of coffin joint and navicular bursa anesthesia should be approached judiciously, as the specificity of each has not been clearly delineated. However, a negative response to analgesia of both the DIPJ and the navicular bursa makes it unlikely that the horse has navicular syndrome.

Diagnostic Imaging

Radiography

Radiography is the most commonly used modality for supporting a clinical diagnosis of navicular syndrome. To fully evaluate the navicular bone, five views are recommended,⁴¹ but at least three views (i.e., lateromedial, 60° dorsoproximal–palmarodistal oblique, 45° palmaroproximal–palmarodistal oblique) should be obtained (**FIGURE 7**). High-quality, correctly positioned radiographs are necessary for an accurate diagnosis. Artifacts associated with improper positioning, technique, and hoof preparation can lead to erroneous information. After removal of the shoes, adequate preparation of the hoof is imperative for obtaining high-quality radiographs. Radiographic artifacts associated with air accumulation within the crevices of the frog appear as lucencies on the radiograph and can mimic fracture lines or cyst-like lesions on the navicular bone. To eliminate air pockets and prevent these artifacts, the hoof should be well packed with a compound having radiographic soft tissue density (e.g., Play-Doh) or should be placed in a plastic container filled with water (the cassette is placed beneath the container). A grid (minimum of 5:1 ratio, with 80 lines/inch) is recommended for dorsopalmar views when using conventional radiography.

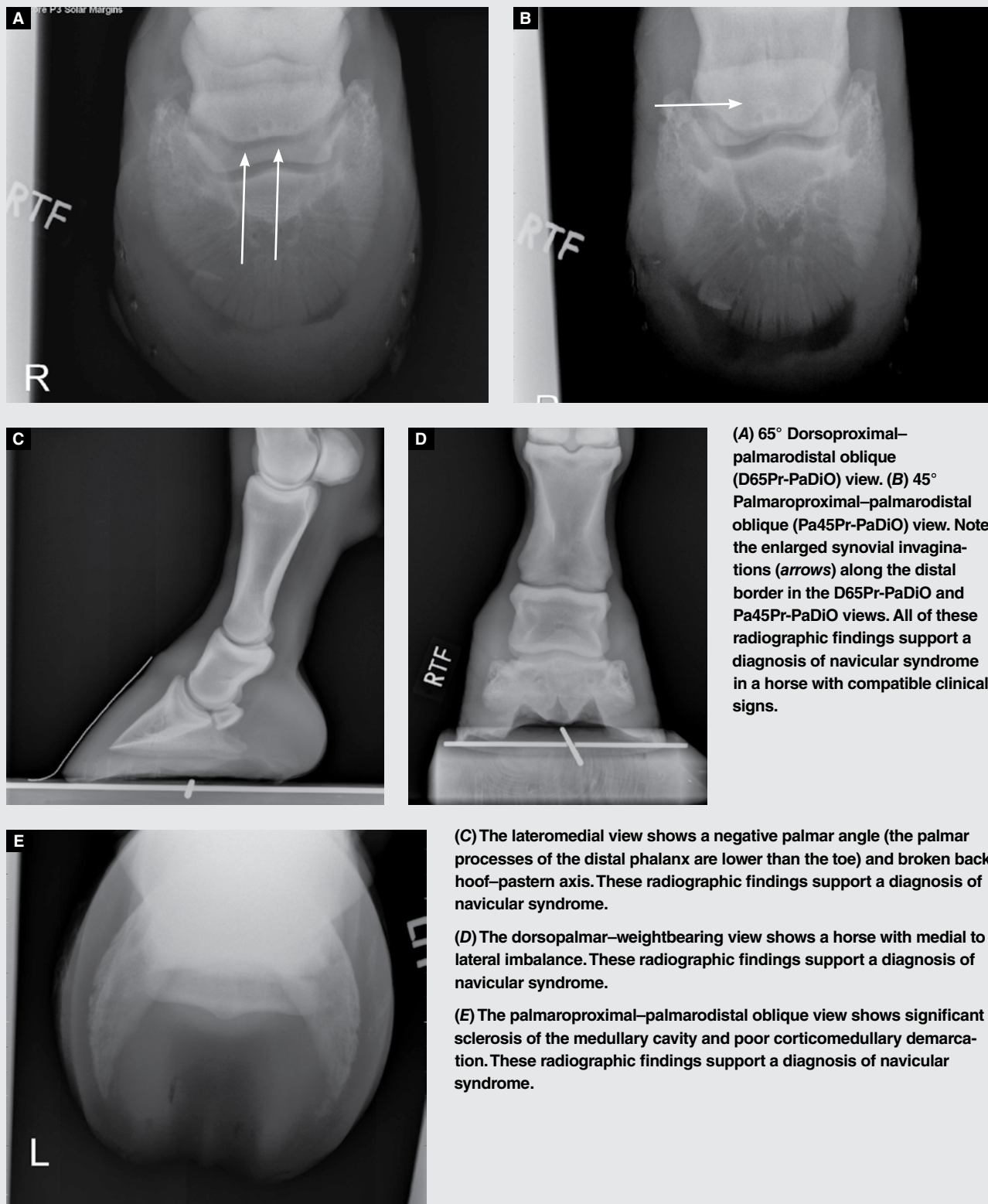FIGURE 6



The palmar midline approach for centesis of the navicular bursa. The hair can be clipped before sterile preparation, but this typically depends on the veterinarian's preference. With the use of aseptic technique, a needle (usually a 3.5-inch, 18-gauge spinal needle) is used to introduce 2 to 3 mL of local anesthetic into the bursa. A common method of entering the navicular bursa is to introduce the spinal needle between the heel bulbs (using aseptic technique), aiming at a point 1 cm distal to the coronary band and halfway between the dorsal hoof wall and heel bulbs. A lateromedial radiograph confirms correct placement of the spinal needle in the bursa.

FIGURE 7

Radiographs of the navicular bone of a horse with clinical signs of navicular syndrome.



Several radiographic changes of the navicular bone have been reported to be compatible with navicular syndrome.⁴²⁻⁴⁴ These changes include increase in size and number of the distal border synovial invaginations, remodeling of the proximal border and extremities of the navicular bone (enthesiophyte formation), flexor cortex erosions, flexor cortex irregularity and thickness, decreased flexor corticomedullary definition (medullary sclerosis), distal border irregularity and fragmentation, mineralization within the collateral ligament of the navicular bone, and cyst-like lesions within the navicular bone (**FIGURE 7**). (Several grading systems exist for evaluating the navicular bone.^{45,46}) A great deal of controversy surrounds the interpretation of these various radiographic findings. In particular, the importance of changes in the number and shape of distal border synovial invaginations has been questioned.⁴⁴ There appears to be some variation between breeds with regard to distal border invaginations, and these and other radiographic changes have been recognized in sound horses.^{47,48} This suggests that radiographic changes of the navicular bone are not pathognomonic for navicular syndrome. Additionally, not all horses with clinical signs of navicular syndrome have radiographic changes associated with the navicular bone. The degree to which changes in the navicular bone (i.e., osseous pathology) contribute to clinical lameness can vary; consequently, other imaging modalities have been used to elucidate what role structures such as soft tissues and vascular supply play in the lameness associated with navicular syndrome.

Ultrasonography

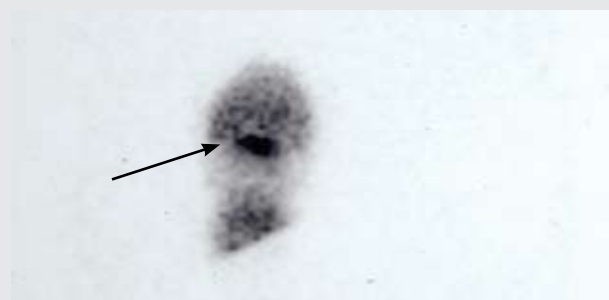
Ultrasonography has been used in a limited capacity in diagnosing navicular syndrome. Ultrasonographic evaluation of the navicular region is difficult because of the hoof capsule and the difficulty in maintaining a 90° angle between the sound beam and the objects of interest when imaging through the heel bulb. However, ultrasonography has been used to assess the distal aspect of the DDFT and the navicular bursa.⁴⁹ Normal anatomy has been described for the proximal navicular bone, navicular bursa, and proximal palmar pouch of the DIPJ.⁴⁹ Imaging through the sole of the hoof is possible if the sole and frog are adequately prepared. The distal impar ligament and distal margin of the navicular bone have been imaged in this manner.⁵⁰ This modality shows promise for clinical application for evaluating the navicular bursa and the DDFT as it passes over the bursa.

Nuclear Scintigraphy

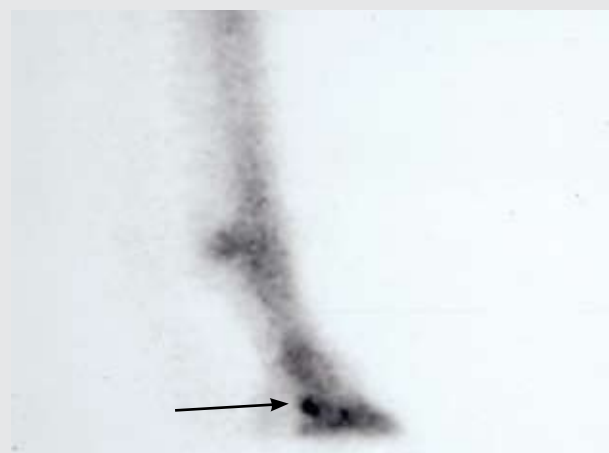Nuclear scintigraphy has been successful in evaluating horses for navicular syndrome (**FIGURE 8**). Scintigraphic imaging depends on the distribution and uptake of a radiopharmaceutical that is injected into the patient. Studies indicate that

FIGURE 8

For scintigraphic evaluation of navicular syndrome, the radionuclide ^{99m}Tc is labeled with a bone-seeking molecule, a diphosphonate, the uptake of which depends on blood flow and osteoblastic/osteoclastic activity.⁵⁶ Two phases of the nuclear scintigraphic study are usually performed: the soft tissue phase and bone phase. Bone-phase views of the lateral and palmar region (solar view) of the affected hoof in horses with clinical navicular syndrome often show increased scintigraphic uptake. These nuclear scintigraphy bone-phase studies show increased radiopharmaceutical uptake (arrows).



Solar view.



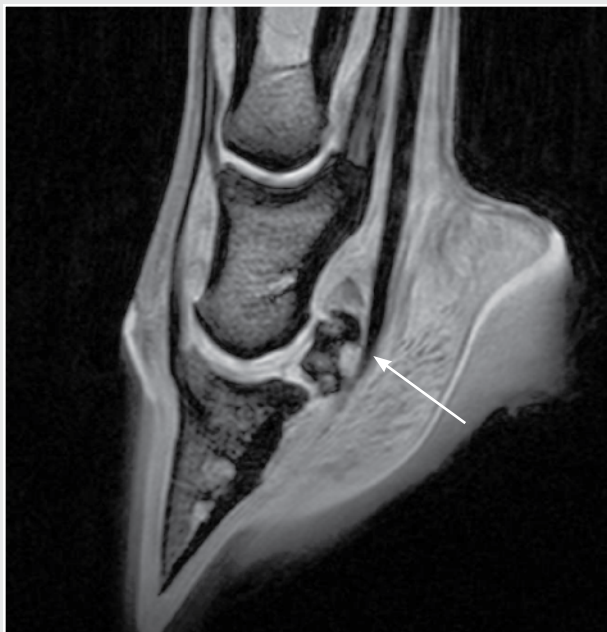Lateral view.

many horses with pain attributed to the navicular region have increased scintigraphic uptake within the navicular bone.^{51,52} Compared with radiography, scintigraphy is much more sensitive in detecting lesions of the bone because radiography requires the loss of at least 50% of the bone's mineral content before lysis is visualized.^{53,54} There is a relatively high incidence of horses that have clinical signs compatible with navicular syndrome, a positive response to intraarticular anesthesia of the DIPJ or intrathecal anesthesia of the navicular bursa, no detectable radiographic abnormalities of the navicular bone, and increased radiopharmaceutical uptake associated with the navicular bone.⁵⁵

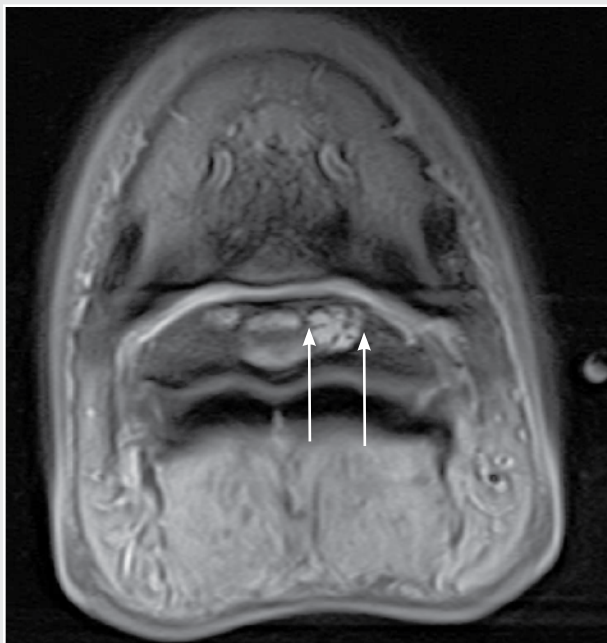
For evaluation of navicular syndrome, the radionuclide technetium 99m (^{99m}Tc) is labeled with a bone-seeking

FIGURE 9

Magnetic resonance imaging of the distal limb of a horse with navicular syndrome. MRI provides the most diagnostic evaluation of the navicular apparatus. The drawbacks of MRI of the distal limb of horses include the lack of availability, the high cost, and the need for general anesthesia.



Sagittal image of the distal limb showing a focal area of increased signal intensity in the flexor cortex of the navicular bone, indicating a cystic lesion (arrow).



Transverse plane image of the same navicular bone with degenerative changes (arrows).

molecule, a diphosphonate, the uptake of which depends on blood flow and osteoblastic/osteoclastic activity.⁵⁶ Two phases of the study are usually performed: (1) soft tissue-phase images are usually acquired 5 to 15 minutes after injection, and (2) bone-phase images are acquired after a 2- to 4-hour delay after injection to allow adequate soft tissue clearance of the radionuclide. Bone-phase views of the lateral and palmar region (solar view) of the affected hoof in horses with clinical navicular syndrome often demonstrate increased scintigraphic uptake. Navicular syndrome is often bilateral; therefore, comparison of uptake in one limb with the contralateral limb is often not helpful because uptake is increased in both navicular bones. Lateral views of these structures appear less sensitive than solar views for demonstrating increased uptake within the navicular region.⁵² This is most likely due to the greater distance and tissue thickness between the navicular region and the face of the gamma camera, decreasing the number of detectable gamma rays emitted from the navicular region.⁵² False-positive lateral views usually result from increased uptake within the distal phalanx, most notably the wings and cartilages of the foot.⁵² The solar view can be used to determine the extent and distribution of uptake within the wings and cartilages of the foot, helping eliminate false-positive lateral views. Therefore, both views should be used in combination to obtain the most useful information, especially when evaluating horses with mild or early navicular bony lesions.

In a study of 264 horses with foot pain, increased radiopharmaceutical uptake was detected in the navicular bone (36.6%), in pool-phase images in the DDFT (13.0%), and at the insertion of the DDFT on the distal phalanx (14.3%).⁵⁷ There was focal increased radiopharmaceutical uptake at the insertion of the medial or lateral collateral ligament of the DIPJ in 9.4% and 1.5% of limbs, respectively. This study showed that positive nuclear scintigraphic results are good predictors of injury or disease of the navicular bone, the DDFT, and the collateral ligaments of the DIPJ.⁵⁷ Overall, nuclear scintigraphy offers a more sensitive diagnostic modality when diagnosing navicular syndrome, but its specificity is lower than that of radiography. When used together, the two modalities can provide useful and complementary information.

Thermography

Thermography is a noninvasive method for measuring heat emitted from a subject.⁵⁸ For medical purposes, it represents the surface temperature of the skin and, therefore, is useful in detecting changes in local circulation and blood flow and, in turn, in detecting inflammation.⁵⁹ Thermography has been used as an adjunct diagnostic modality to evaluate navicular syndrome. In one study, the thermal pattern demonstrated by horses with navicular syndrome was char-

acterized not by increased blood flow but by decreased blood flow.⁵⁹ Although thermography is not commonly used to diagnose navicular syndrome, it can provide additional, potentially useful information.

Computed Tomography

Computed tomography (CT) generates cross-sectional images of an anatomic site by using x-rays and computer integration. The internal anatomy of a structure is reconstructed by a computer from numerous x-ray projections through the object.⁶⁰ This produces an image that lacks superimposition of overlying structures and has superior soft tissue contrast compared with conventional radiography.⁶¹ The normal anatomy of the equine digit⁶² has been used in the postmortem evaluation of lameness attributable to the foot and in clinical cases, including patients with suspected navicular syndrome.^{63,64} Both reports found resolution of bony detail and soft tissue contrast to be superior on CT than on conventional radiography. In one report,⁶³ investigators visualized pathology within the DDFT, along with numerous bony changes affecting the navicular bone. The significance of these findings is that, for the first time, a single imaging modality was able to define lesions within the soft tissue and bone. The limitations of this modality include the high cost of setup and upkeep, the relative lack of availability for veterinary use, the need for general anesthesia, and machine design (namely, the gantry, which can be small and cumbersome for equine patients).

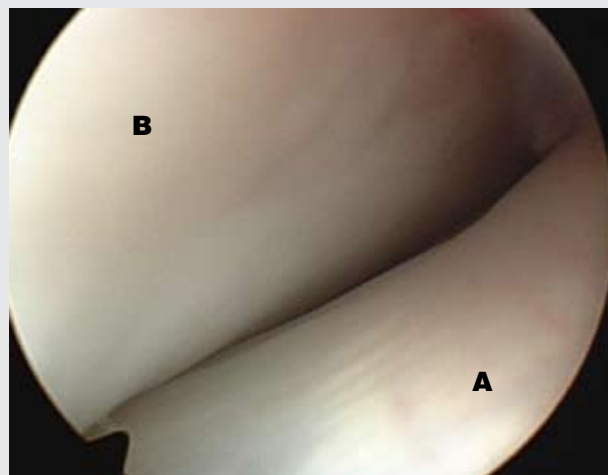
Magnetic Resonance Imaging

Magnetic resonance imaging (MRI) has recently been used to evaluate navicular syndrome. This technique does not use ionizing radiation but depends on the resonance of protons within the body's tissues (namely, fat and water) in response to magnetic fields and radiofrequency waves to produce an image.⁶⁵ The difference in the chemical composition of tissues and their proton density determines the signal intensity and, therefore, the image.⁶⁵ MRI produces the most superior soft tissue contrast of all imaging methods mentioned in this article and allows reconstruction of the object being imaged in numerous planes. The combination of these factors makes MRI ideal for imaging complex structures with soft tissue components, such as joints.⁶⁶

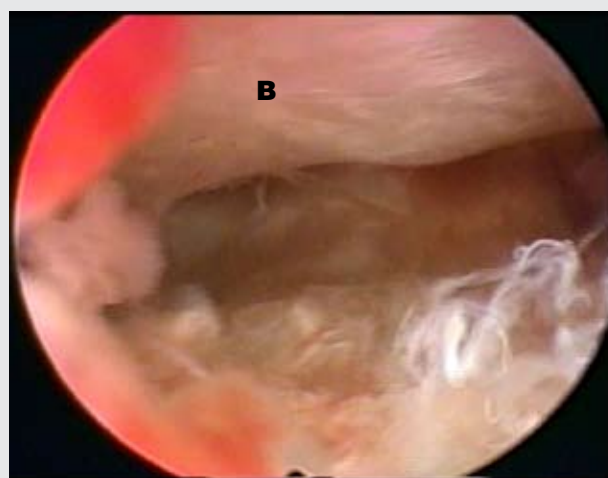
Only recently has MRI become available to equine patients⁶⁷; before this availability, MRI had been performed only on cadaver limbs.^{63,68,69} MRI of the digit in horses with clinical lameness associated with navicular syndrome has revealed osseous and soft tissue changes, including enlarged synovial fossae, fragmentation of the distal navicular bone, and cyst formation on the midsagittal ridge, as well as areas of attenuation within the DDFT^{63,67} (FIGURE 9). Murray et al⁷⁰

FIGURE 10

Arthroscopic examination of the navicular bursa.



Normal endoscopic view of the navicular bursa via an arthroscope. (Deep digital flexor tendon [A], navicular bone [B])



Endoscopic view of a horse with navicular bursitis. (Navicular bone [B])

directly compared histology and MRI, revealing that signal alterations on MRI represent tissue-level changes, including structural damage, fibroplasia, fibrocartilaginous metaplasia, and hemosiderosis in ligaments and tendons; trabecular damage; osteonecrosis; cortical defects; increased vascularity in bone; and fibrocartilage defects. MRI had high specificity for lesions of the DDFT, collateral sesamoidean ligament, navicular bursa, and navicular bone.⁷⁰ In another study⁷¹ of 264 horses with unilateral or bilateral foot pain, MRI indicated that lesions of the DDFT were most common (82.6% of feet). These lesions were most commonly located at the level of the collateral sesamoidean ligament (59.4%) and the navicular bone (59.0%). Core lesions in the DDFT predominated

at the level of the proximal phalanx (90.3%). At the level of the collateral sesamoidean ligament and navicular bone, the most common lesions in the DDFT were core lesions, sagittal splits, and dorsal abrasions.⁷¹ Lesions of the distal sesamoidean impar ligament (38.2%) were more common than those of the collateral sesamoidean ligament (10.5%), but the presence of either was associated with abnormalities of the navicular bone.⁷¹

Drawbacks of this imaging modality include its limited availability to equine patients due to the high cost of setup and upkeep, the design of some systems (which is cumbersome for equine patients), and the need for general anesthesia. Standing MRI equipment is available; however, the ability to obtain a consistently high-quality image proximal to the foot is complicated by motion.

Arthroscopic Examination

Arthroscopic examination of the navicular bursa permits evaluation of the fibrocartilage on the flexor surface of the navicular bone, the navicular bursa itself, and the overlying dorsal surface of the DDFT as well as limited visualization of the distal sesamoidean impar ligament^{72,73} (FIGURE 10). Therefore, it is possible to definitively identify adhesions between the DDFT and the palmar aspect of the navicular bone, thinning or full-thickness erosion of the flexor fibrocartilage of the bone, fibrillation of the dorsal aspect of the DDFT, and synovitis of the bursa. In a retrospective study by Smith et al,⁷⁴ 23 bursae were examined arthroscopically in 20 horses. Tears in the DDFT were seen in all horses (22 bursae). In eight bursae, cartilage lesions were also present; in one bursa, this was the only abnormal finding. CT and low-field MRI predicted tendon lesions in most cases but failed to identify the cartilage damage.⁷⁴ Based on this study, navicular bursoscopy allows comprehensive diagnostic evaluation of the navicular bursa, a significant portion of the navicular bone, and surrounding anatomic structures; this can provide additional useful information in some horses with navicular syndrome.

Conclusion

The diagnosis of navicular syndrome is often complex because the pathogenesis is still unclear and the exact source of the pain is neither well defined nor consistent among horses. With new diagnostic imaging and techniques, veterinarians are learning that anatomic structures other than the navicular bursa, navicular bone, and DDFT may play an important role in lameness associated with navicular syndrome. Often, these horses present late in the course of the condition, when destructive changes have already occurred; thus, treatment often addresses pain modification rather than inhibition of the pathologic processes.

References

1. Stashak TS. *Navicular Syndrome (Navicular Disease or Navicular Region Pain)*. 5th ed. Philadelphia: Lippincott Williams & Wilkins; 1998.
2. Turner TA. Navicular disease management: shoeing principles. *Proc AAEP* 1986; 625-633.
3. Colles C. Navicular disease and its treatment. *In Pract* 1982;4:29-36.
4. Rijkenhuizen AB, Nemeth F, Dik KJ, et al. Development of the navicular bone in foetal and young horses, including the arterial supply. *Equine Vet J* 1989;21:405-412.
5. Getty R. Equine osteology. In: Getty R, ed. *The Anatomy of the Domestic Animals*. 5th ed. Philadelphia: WB Saunders; 1975:291-296.
6. Poulos PW, Smith MF. The nature of enlarged "vascular channels" in the navicular bone of the horse. *Vet Radiol* 1988;60-64.
7. Kainer RA. Clinical anatomy of the equine foot. *Vet Clin North Am Equine Pract* 1989;5:1-27.
8. Getty R. Equine syndesmosis. In: Getty R, ed. *The Anatomy of the Domestic Animals*. Philadelphia: WB Saunders; 1975:361-362.
9. Getty R. Equine myology. In: Getty R, ed. *The Anatomy of the Domestic Animals*. Philadelphia: WB Saunders; 1975:428-431.
10. Jann H, Henry G, Berry A, et al. Arthrographic observations of the equine distal interphalangeal joint (articulationes interphalangeae distalis manus) and navicular bursa (bursa podotrochlearis). *Anat Histol Embryol* 1991;20(1):30-36.
11. Gibson KT, McIlwraith CW, Park RD. A radiographic study of the distal interphalangeal joint and navicular bursa of the horse. *Vet Radiol* 1990;22-25.
12. Sack WO, Habel RE. *Rooney's Guide to the Dissection of the Horse*. 5th ed. Ithaca, NY: Veterinary Textbooks; 1977.
13. Bowker RM, Rockershouser SJ, Linder K, et al. A silver-impregnation and immunocytochemical study of innervation of the distal sesamoid bone and its suspensory ligaments in the horse. *Equine Vet J* 1994;26:212-219.
14. Bowker RM, Rockershouser SJ, Vex KB, et al. Immunocytochemical and dye distribution studies of nerves potentially desensitized by injections into the distal interphalangeal joint or the navicular bursa of horses. *JAVMA* 1993;203:1708-1714.
15. Bowker RM, Linder K, VanWalfen KK, et al. Distribution of local anesthetic injected into the distal interphalangeal joint and podotrochlear bursa: an experimental study. *Pferdeheilkunde* 1996;609-612.
16. Rijkenhuizen AB, Nemeth F, Dik KJ, et al. The arterial supply of the navicular bone in adult horses with navicular disease. *Equine Vet J* 1989;21:418-424.
17. Colles CM, Hickman J. The arterial supply of the navicular bone and its variations in navicular disease. *Equine Vet J* 1977;9:150-154.
18. Rooney JR. The foreleg. In: *The Mechanics of the Horse*. Malabar, FL: Robert E. Kreiger; 1980:60-61.
19. Wright IM, Douglas J. Biomechanical considerations in the treatment of navicular disease. *Vet Rec* 1993;133:109-114.
20. Pleasant RS, Chrisman MC. Navicular disease in horses: pathogenesis and diagnosis. *Vet Med* 1997;250-257.
21. Pool RR, Meagher DM, Stover SM. Pathophysiology of navicular syndrome. *Vet Clin North Am Equine Pract* 1989;5:109-129.
22. Colles CM. Ischaemic necrosis of the navicular bone and its treatment. *Vet Rec* 1979;104:133-137.
23. Svalastoga E. Navicular disease in the horse: a microangiographic investigation. *Nord Vet Med* 1983;131-139.
24. Ostblom LC, Lund C, Melsen F. Navicular bone disease: results of treatment using egg-bar shoeing technique. *Equine Vet J* 1984;16:203-206.
25. Thompson KN, Rooney JR, Petrites-Murphy MB. Considerations on the pathogenesis of navicular disease. *J Equine Vet Sci* 1991;4-8.
26. Ostblom L, Lund C, Melsen F. Navicular bone disease: a comparative histomorphometric study. *Equine Vet J* 1989;21:431-433.
27. Adams OR. Navicular disease (navicular bursitis, podotrochleitis). In: Adams OR, ed. *Adams' Lameness in Horses*. 3rd ed. Philadelphia: Lea & Febiger; 1974:260-274.
28. Pleasant RS, Baker GJ, Foreman JH, et al. Intraosseous pressure and pathologic changes in horses with navicular disease. *Am J Vet Res* 1993;54:7-12.
29. Svalastoga E, Reimann I, Nielsen K. Changes of the fibrocartilage in navicular disease in horses: a histological and histochemical investigation of navicular bones. *Nord Vet Med* 1983;31-37.
30. Svalastoga E, Smith M. Navicular disease in the horse. The subchondral bone pressure. *Nord Vet Med* 1983;35:31-37.
31. Svalastoga E, Nielsen K. Navicular disease in the horse: the synovial membrane of bursa podotrochlearis. *Nord Vet Med* 1983;35:28-30.
32. Wright IM, Kidd L, Thorp BH. Gross, histological and histomorphometric features of the navicular bone and related structures in the horse. *Equine Vet J* 1998;30:220-234.
33. Lowe JE. Sex, breed, and age incidence of navicular disease. *Proc AAEP* 1976:37.
34. Bos H, van der Meij GJ, Dik KJ. Heredity of navicular disease. *Vet Q* 1986;8:68-72.

35. Dyson SJ, Kidd L. A comparison of responses to analgesia of the navicular bursa and intra-articular analgesia of the distal interphalangeal joint in 59 horses. *Equine Vet J* 1993;25:93-98.
36. Pleasant RS, Moll HD, Ley WB, et al. Intra-articular anesthesia of the distal interphalangeal joint alleviates lameness associated with the navicular bursa in horses. *Vet Surg* 1997;26:137-140.
37. Dyson S. Comparison of response to analgesia of the navicular bursa and intra-articular analgesia of the distal interphalangeal joint in 102 horses. *Proc AAEP* 1995;234-239.
38. Schumacher J, Steiger R, Schumacher J, et al. Effects of analgesia of the distal interphalangeal joint or palmar digital nerves on lameness caused by solar pain in horses. *Vet Surg* 2000;29:54-58.
39. Turner TA. Diagnosis and treatment of the navicular syndrome in horses. *Vet Clin North Am Equine Pract* 1989;5:131-144.
40. Schumacher J, Schumacher J, DeGraves F, et al. A comparison of the effects of 2 volumes of local anesthetic solution in the distal interphalangeal joint of horses with lameness caused by solar toe or solar heel pain. *Equine Vet J* 2001;33:265-268.
41. Park RD. Radiographic examination of the equine foot. *Vet Clin North Am Equine Pract* 1989;5:47-66.
42. Poulos PW. Correlation of radiographic signs and histological changes in navicular disease. *Proc AAEP* 1983;241-255.
43. MacGregor CM. Radiographic assessment of navicular bones based on changes in the distal nutrient foramina. *Equine Vet J* 1986;18:203-206.
44. Wright IM. A study of 118 cases of navicular disease: radiological features. *Equine Vet J* 1993;25:493-500.
45. Dik K. Radiographic examination. In: Wagenaar G, ed. *The Pre-purchase Examination of the Horse*. 2nd ed. Utrecht, The Netherlands: Bunge; 1992.
46. Dyson S. Navicular disease and other soft tissue causes of palmar foot pain. In: Ross MW, ed. *Diagnosis and Management of Lameness in the Horse*. St. Louis: Saunders; 2003:286-299.
47. Turner TA, Kneller SK, Babertscher RR, et al. Radiographic changes in the navicular bones of normal horses. *Proc AAEP* 1986;309-313.
48. Kazer-Hotz B, Ueltschi G. Radiographic appearance of the navicular bone in sound horses. *Vet Radiol Ultrasound* 1992;9:17.
49. Hauser ML, Rantanen NW, Modransky PD. Ultrasound examination of the distal interphalangeal joint, navicular bursa, navicular bone, and deep digital flexor tendon. *J Equine Vet Sci* 1982;2:95-97.
50. Grewal JS, McClure SR, Booth LC, et al. Assessment of the ultrasonographic characteristics of the podotrochlear apparatus in clinically normal horses and horses with navicular syndrome. *JAVMA* 2004;225:1881-1888.
51. Trout DR, Hornof WJ, O'Brien TR. Soft tissue- and bone-phase scintigraphy for diagnosis of navicular disease in horses. *JAVMA* 1991;198:73-77.
52. Keegan KG, Wilson DA, Lattimer JC, et al. Scintigraphic evaluation of 99mTc-methylene diphosphonate uptake in the navicular area of horses with lameness isolated to the foot by anesthesia of the palmar digital nerves. *Am J Vet Res* 1996;57:415-421.
53. Wilcox JR, Moniot AL, Green JP. Bone scanning in the evaluation of exercise-related stress injuries. *Radiology* 1977;123:699-703.
54. Kealy KJ. Bones and joints. *Diagnostic Radiology of the Dog and Cat*. Philadelphia: WB Saunders; 1987:312.
55. Dyson SJ. Subjective and quantitative scintigraphic assessment of the equine foot and its relationship with foot pain. *Equine Vet J* 2002;34:164-170.
56. Chambers MD. Bone imaging: the diphosphonates. In: Daniel GB, ed. *Handbook of Veterinary Nuclear Medicine*. Raleigh: North Carolina State University Press; 1996:49-59.
57. Dyson S, Murray R. Verification of scintigraphy imaging for injury diagnosis in 264 horses with foot pain. *Equine Vet J* 2007;39:350-353.
58. Turner TA. Thermography as an aid to the clinical lameness evaluation. *Vet Clin North Am Equine Pract* 1991;7:311-338.
59. Turner TA, Fessler JF, Lamp M, et al. Thermographic evaluation of horses with podotrochlosis. *Am J Vet Res* 1983;44:535-539.
60. Curry TS, Dowdey JE, Murray RC. Computed tomography. In: Murry RC, ed. *Christensen's Physics of Diagnostic Radiology*. 4th ed. Philadelphia: Lea & Febiger; 1990:289-290.
61. Hathcock JT, Stickle RL. Principles and concepts of computed tomography. *Vet Clin North Am Small Anim Pract* 1993;23:339.
62. Peterson PR, Bowman KE. Computed tomographic anatomy of the distal extremity of the horse. *Vet Radiol Ultrasound* 1988;29:147-156.
63. Whitton RC, Buckley C, Donovan T, et al. The diagnosis of lameness associated with distal limb pathology in a horse: a comparison of radiography, computed tomography and magnetic resonance imaging. *Vet J* 1998;155:223-229.
64. Britt LG, Tucker RL, Sande RD, et al. Magnetic resonance and computed tomography of the equine foot. *Vet Radiol Ultrasound* 1998;39:600.
65. Smith HJ, Ranallo FN. Introduction. In: Fanalio FN, ed. *A Non-mathematical Approach to Basic MRI*. Madison, WI: Medical Physics Publishing Corp; 1989:1-3.
66. Peterfy CG, Linares R, Steinbach LS. Recent advances in magnetic resonance imaging of the musculoskeletal system. *Radiol Clin North Am* 1994;32:291.
67. Widmer WR, Buckwalter KA, Fessler JF, et al. Use of radiography, computed tomography and magnetic resonance imaging for evaluation of navicular syndrome in the horse. *Vet Radiol Ultrasound* 2000;41:108-116.
68. Park RD, Nelson TR, Hoopes PJ. Magnetic resonance imaging of the normal equine digit and metacarpophalangeal joint. *Vet Radiol* 1987;29:105-116.
69. Denoix JM, Crevier N, Roger B, et al. Magnetic resonance imaging of the equine foot. *Vet Radiol Ultrasound* 1993;34:405-411.
70. Murray RC, Blunden TS, Schramme MC, et al. How does magnetic resonance imaging represent histologic findings in the equine digit? *Vet Radiol Ultrasound* 2006;47:17-31.
71. Dyson S, Murray R. Magnetic resonance imaging evaluation of 264 horses with foot pain: the podotrochlear apparatus, deep digital flexor tendon and collateral ligaments of the distal interphalangeal joint. *Equine Vet J* 2007;39:340-343.
72. Cruz AM, Pharr JW, Bailey JV, et al. Podotrochlear bursa endoscopy in the horse: a cadaver study. *Vet Surg* 2001;30:539-545.
73. Wright IM, Phillips TJ, Walmsley JP. Endoscopy of the navicular bursa: a new technique for the treatment of contaminated and septic bursae. *Equine Vet J* 1999;31:5-11.
74. Smith MR, Wright IM, Smith RK. Endoscopic assessment and treatment of lesions of the deep digital flexor tendon in the navicular bursae of 20 lame horses. *Equine Vet J* 2007;39:18-24.

3 CE
CREDITS

CE TEST

This article qualifies for 3 contact hours of continuing education credit from the Auburn University College of Veterinary Medicine. Subscribers must take individual CE tests online and get real-time scores at Vetlearn.com. Those who wish to apply this credit to fulfill state relicensure requirements should consult their respective state authorities regarding the applicability of this program.

1. The navicular bone is completely ossified by approximately day _____ of gestation.
 - a. 100
 - b. 150
 - c. 200
 - d. 325
2. The distal sesamoidean impar ligament arises from the distal margin of the navicular bone and extends to the
 - a. flexor surface of the first phalanx.
 - b. extensor surface of the middle phalanx.
 - c. flexor surface of the distal phalanx.
 - d. flexor surface of the middle phalanx.
3. The navicular bursa is located between the navicular bone and the
 - a. DDFT.
 - b. distal phalanx.
 - c. superficial flexor tendon.
 - d. distal sesamoidean impar ligament.
4. The primary function of the navicular bone is to
 - a. cushion the supporting structures of the hoof.
 - b. provide a constant angle of insertion for the DDFT.
 - c. support the coffin joint.
 - d. supply blood to the navicular bursa.
5. Most research indicates that navicular syndrome is most similar to
 - a. osteochondrosis.
 - b. osteoarthritis.
 - c. ischemia.
 - d. hyperemia.
6. What two breeds in North America have a higher incidence of navicular syndrome?
 - a. Morgan and Arabian
 - b. Standardbred and Morgan
 - c. Quarter horse and Thoroughbred
 - d. Appaloosa and Arabian
7. Local anesthesia of the _____ nerves should be used to eliminate the lameness associated with navicular syndrome.
 - a. medial and lateral deep metacarpal
 - b. medial and lateral palmar digital
 - c. ulnar and median
 - d. medial and lateral palmar
8. Which radiographic view(s) best delineate(s) radiographic changes associated with navicular syndrome?
 - a. Pa45Pr-PaDiO
 - b. D60Pr-PaDiO
 - c. lateromedial
 - d. all of the above
9. Which statement is not a reason why radiographic evidence of navicular syndrome is not pathognomonic for the disease?
 - a. Navicular changes have been recognized in sound horses.
 - b. Not all horses with clinical signs of navicular syndrome have radiographic changes associated with the navicular bone.
 - c. The degree that changes to the navicular bone contribute to lameness is unknown.
 - d. Horses with navicular syndrome have enlarged vascular channels along the distal margin of the navicular bone.
10. Horses with navicular syndrome show a pain response (i.e., limb withdrawal) to pressure applied with hoof testers over the
 - a. solar margins of the toe.
 - b. solar margins of the heel.
 - c. middle third of the frog.
 - d. dorsal third of the frog.