

What Is Your Diagnosis?

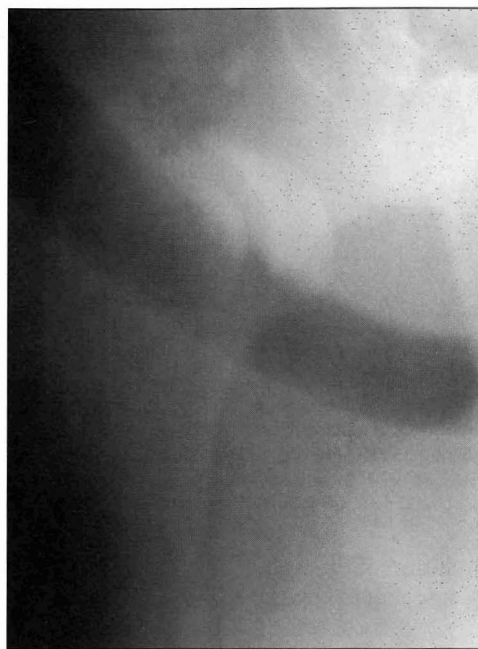

Figure 1—Mediolateral radiographic view of the right scapulohumeral joint of a horse examined because of severe lameness of 6 weeks' duration.

History

A 5-year-old Quarter Horse gelding was examined because of severe right forelimb lameness of 6 weeks' duration. Physical examination revealed that the horse was able to bear only a slight amount of weight on the affected limb. Moderate muscle atrophy was evident over the right shoulder region, and manipulation of the proximal portion of the limb elicited signs of pain. Injury to the scapulohumeral joint was suspected, and radiographic views of this joint were obtained (Fig 1).

Determine whether additional imaging studies are required, or make your diagnosis from Figure 1—then turn the page ▶

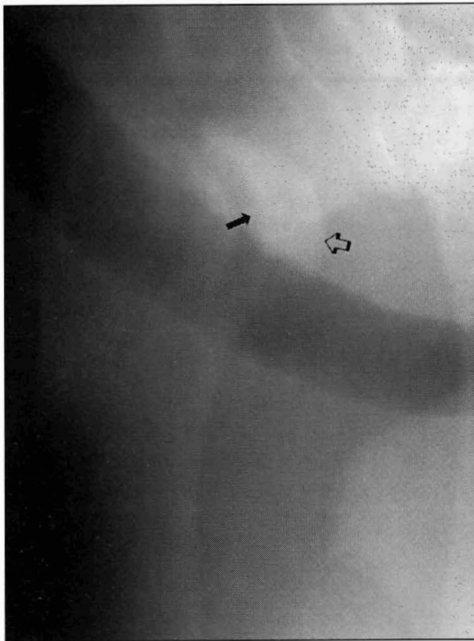


Figure 2—Same radiographic view as Figure 1. Notice the incongruity between articular surfaces of the humeral head and glenoid cavity. The articular surface of the humeral head (open arrow) can be seen above the articular surface of the glenoid cavity (closed arrow).

Diagnosis

Radiographic diagnosis—Subluxation of the right humerus. Secondary degenerative changes are evident.

Comments

Luxation of the scapulohumeral joint is a rare injury that can cause severe lameness in horses.¹⁻⁴ The scapulohumeral joint does not have ligaments for support; therefore, the surrounding musculature and tendons, along with the large humeral head, provide stability and help prevent dislocation.⁵

Causes of scapulohumeral luxation in horses¹⁻⁴ include falling with the shoulder joint in the flexed position, collateral instability, or excessive tension placed on the distal portion of the limb. Collateral instability of the scapulohumeral joint decreases the strength of surrounding supporting structures and predisposes the humeral head to luxate from the glenoid cavity.⁶ Surrounding soft tissue often is severely damaged during luxation of the humeral head.

A diagnosis of scapulohumeral luxation can be made on the basis of clinical signs, visual examination, and findings on manipulation of the affected limb. Most horses with this condition have an acute grade-5/5 lameness. Shortening of the affected limb, swelling in the region of the scapulohumeral joint, and muscle atrophy from disuse of the limb may be evident.^{2,7} Flexion and extension of the proximal portion of the limb elicits a painful response.² Palpation of prominences of the proximal portion of the humerus may provide clues to the orientation of the luxated humeral head. When the humeral head is luxated cranially, the greater tu-

berosity and the head of the humerus can be palpated cranial to the glenoid cavity. The lateral lip of the glenoid cavity may be palpable in the case of medial luxation. If luxation of the humeral head is lateral, the proximal lateral prominences of the humerus may be easily seen and palpated, as for the horse of this report. Radiography can be used to confirm scapulohumeral luxation and rule out other shoulder injuries causing acute lameness, such as fractures of the supraglenoid tuberosity, humeral head, scapula, or glenoid cavity.

General anesthesia is required for reduction of humeral head luxations. Suspending the horse from a hoist so that the surrounding shoulder musculature becomes fatigued may facilitate reduction.⁴ Muscle relaxants also may be of assistance. Scapulohumeral arthroscopy may be required to determine the degree of damage to articular surfaces or to remove bone fragments resulting from the luxation.³

Prognosis for horses with shoulder luxations can be favorable if soft tissue damage is minimal and the injury is treated promptly.¹⁻⁴ Horses often begin bearing weight on the affected limb immediately after reduction of the humeral head.⁴ Prognosis is poor if lameness does not improve during the first 2 weeks after reduction of the humeral head.² Long-term prognosis for athletic function depends on the extent of damage to the scapulohumeral joint and surrounding soft tissue.

Because lameness was chronic and the condition was severe, owners of the horse of this report requested that it be euthanatized. Postmortem findings included lateral subluxation of the scapulohumeral joint and marked eburnation of the articular surfaces. Considerable soft tissue damage was also evident. A severe erosion in the medial aspect of the humeral head was caused by friction created between this portion of the humeral head and the lateral lip of the glenoid cavity.

1. Colbourne CM, Yovich JV, Bolton JR. The diagnosis and successful treatment of shoulder luxation in a pony. *Aust Equine Vet* 1991;9:100-102.

2. Stashak TS. Lameness. In: Stashak TS, ed. *Adam's lameness in horses*. 4th ed. Philadelphia: Lea & Febiger, 1987;486-785.

3. Madison JB, Young D, Richardson D. Repair of shoulder luxation in a horse. *J Am Vet Med Assoc* 1991;198:455-456.

4. Wilson RG, Reynolds WT. Scapulohumeral luxation with treatment by closed reduction in a horse. *Aust Vet J* 1984;61:300-301.

5. Sisson S. Equine syndesmology. In: Getty R, ed. *Sisson and Grossman's the anatomy of the domestic animals*. 5th ed. Philadelphia: WB Saunders Co, 1975;349-375.

6. Honnas CM. Surgical treatment of selected musculoskeletal disorders of the forelimb. In: Auer JA, ed. *Equine surgery*. Philadelphia: WB Saunders Co, 1992;985-1054.

7. Turner S. Large animal orthopedics. In: Jennings PB, ed. *The practice of large animal surgery*. Philadelphia: WB Saunders Co, 1984;768-949.

This report was submitted by Dwayne H. Rodgerson, DVM; and R. Reid Hanson, DVM; from the Department of Large Animal Medicine and Surgery, College of Veterinary Medicine, Auburn University, Auburn, AL 36849-5522.