



Continuing Education Article #6
Refereed Peer Review

FOCAL POINT

- ★ Performing skin grafts in the field can lessen the healing time of wounds and improve cosmetic outcome.

KEY FACTS

- Skin grafts are classified according to their source, thickness, and blood supply, p. 872.
- The success of a graft is based on its fibrinous adherence to the bed, plasmatic imbibition, revascularization of the graft, and the organization of the grafted wound with collagen-secreting fibroblasts, p. 873.
- After injury, formation of a healthy bed of granulation tissue takes at least 5 days, p. 873.
- Chlorhexidine diacetate, at a concentration of 0.05%, is a useful antimicrobial agent in the postoperative care of skin grafts, p. 879.

Equine Skin Grafting: Principles and Field Applications*

Auburn University

Suzann A. Carson-Dunkerley, DVM

R. Reid Hanson, DVM

When horses incur cutaneous wounds that cannot be sutured because of significant cutaneous damage or loss of deeper tissue, healing by second intention must occur. However, large wounds that heal by second intention heal slowly, and the scars that form are often cosmetically unappealing.^{1,2} Skin grafting may reduce healing time, improve cosmesis, and allow a horse to return to function sooner than if the wound were allowed to heal by second intention.³ With the proper equipment and expertise, many skin grafting techniques can be performed on the farm.² This article describes grafting procedures that can be conveniently performed with the horse standing or anesthetized with a short-acting general anesthetic.

CLASSIFICATION

Skin grafts are classified on the basis of three characteristics: source, thickness, and blood supply.² Grafts that are classified according to the source include autogenous grafts, homografts, and xenografts. Autogenous grafts (autografts) are taken from one site and moved to another site on the same animal.^{2,4,5} Homografts (allografts) are transferred between genetically different individuals of the same species.⁵ Xenografts (heterografts) are transferred between individuals of different species.⁵ With autogenous grafting, an immunologic reaction against the donor skin does not occur.

Grafts that are classified by thickness include split-thickness grafts (which are composed of the epidermis and a portion of the dermis) and full-thickness grafts (which include the epidermis and all of the dermis).⁶ Both types are readily accepted by horses.^{7,8} Because full-thickness grafts are easier to obtain and because harvesting them does not require specialized equipment (e.g., a dermatome), full-thickness grafting is easier to perform in the field.⁶

*Publication Series No. 2541, College of Veterinary Medicine, Auburn University, Auburn, AL 36849.

Grafts that are classified by blood supply are the free graft and the pedicle graft. A free graft is devoid of blood supply; a pedicle graft maintains its own blood supply.^{2,5} Because pedicle grafting requires general anesthesia to isolate the required nutrient arterial vessel, free grafting is more practical for use in the field.²

Free grafts are further classified as island grafts (e.g., pinch, punch, and tunnel grafts) and sheet grafts. Sheet grafts can be split-thickness or full-thickness and can be applied as solid or meshed sheets. Pinch, punch, tunnel, and sheet grafting can be applied in the field, with the horse standing or recumbent, using short-acting general anesthesia. Sheet grafts provide more complete dermal coverage of the wound; island grafts provide dermal tissue only at the graft site and provide epithelial coverage in between. Grafts help to control infection, provide dermal coverage of the wound, and stimulate epithelialization from the epithelial edges of the wound and graft.^{2,9}

HEALING OF GRAFTS

The success of grafting is based on four events: (1) fibrinous adherence of the graft to its bed, (2) plasmatic imbibition (passive absorption of nutrients by the vessels of the graft), (3) revascularization of the graft, and (4) organization of the grafted wound with collagen-secreting fibroblasts.⁵ The graft adheres within minutes of implantation.^{2,6} Fibrin, formed from fibrinogen, is brought into the recipient site by the surrounding vessels and attaches the graft to its bed.¹⁰ For the first few days after grafting, the delicate fibrinous attachment is the sole method of adhesion.⁶ Early immobilization to protect this delicate attachment thus is critical to the acceptance of the graft.¹¹

Before the graft is revascularized, it must survive by plasmatic imbibition. This is the process by which the graft bed provides an oxygen-rich, plasmalike nutrient fluid for absorption into the dilated vessels of the graft.^{11,12} The duration of plasmatic imbibition depends on the quality of the recipient site bed. The more vascular the recipient bed, the faster the graft is revascularized and the less it must rely on plasmatic imbibition.^{10,12}

The graft revascularizes by two processes: (1) vascular anastomoses through a direct connection of graft and host vessels (inosculation) and (2) ingrowth of host vessels into the dermis of the graft.^{11,13} Inosculation usually begins during the first 2 days, restoring circulation to the graft by the fourth to seventh day.^{10,13,14} Revascularization by invasion of new vessels begins at 4 to 12 days.² When revascularization is well established, the fibrinous attachment of the graft is infiltrated with fibro-

blasts. These cells secrete collagen and ground substance into the wound, increasing the tensile strength of the attachment of the graft.^{10,15}

PREPARATION OF THE RECIPIENT SITE

Sheet grafts are best applied to fresh wounds that have no granulation tissue, but such grafts also can be applied to granulating wounds. Island grafts, however, can be applied only to granulating wounds. The granulation tissue to which grafts are applied should be newly formed, richly vascular, firm, and free of purulent discharge.^{10,16,17} The presence of advancing epithelium at the margin of the wound is generally a good indicator of the bed's health and capacity to accept a graft.^{10,17} Formation of a healthy bed of granulation tissue requires at least 5 days after injury.¹⁰

Because wounds in horses are frequently treated for weeks before the decision to graft is made, the granulation tissue is often mature and contains more fibrous tissue and a poorer blood supply than would a fresh bed of granulation tissue. Consequently, the ability to accept a graft is less than optimum.¹ Before the graft is applied, the mature granulation tissue must be excised to below the skin surface to allow development of a healthier, more vascular granulation tissue bed. Because of the lack of innervation, granulation tissue can be excised with the horse standing.¹⁷ Deep crevices and depressions in the tissue should be excised so that the wound is smooth, allowing better contact with and thus better acceptance of the graft.³

Studies indicate that trimming granulation tissue as much as 4 days before skin grafting may increase acceptance of grafts.^{4,18} Because of the significant amount of hemorrhage that results from such trimming, the bed should be trimmed no less than 24 hours before grafting. Wounds that are apparently infected can be cultured for bacterial identification and antimicrobial sensitivity testing.¹⁸

After debridement, the wound should be covered with a nonadhesive pad and a well-padded bandage. If the wound is at a highly mobile site (e.g., the metacarpophalangeal joint), the site should be stabilized by a splint incorporated into the bandage before grafting to accustom the horse to the decreased range of motion of the joint.¹⁷ The acceptance of the graft is positively influenced by the use of appropriate bandages that prevent movement between the graft and the recipient bed and that help protect the delicate granulation tissue from bruising.^{3,4}

For grafts to be accepted, the concentration of bacteria in the wound must be minimized.¹⁹ *β*-hemolytic *Streptococcus*, *Proteus*, and *Pseudomonas* species are capable of producing destructive proteolytic enzymes that

degrade fibrinous attachments between the graft and recipient bed.^{2,3,6,18,19} These bacteria also produce copious purulent discharge that can separate the graft from its bed.^{2,3,6,18,19}

Topical treatment of infected granulating wounds with appropriate antimicrobial drugs is more effective than systemic treatment.^{17,20} Systemically administered antimicrobial drugs are often incapable of achieving therapeutic concentrations in the granulation tissue because fibrin in the wound prevents penetration of the drug to the surface of the wound.^{17,20} Systemic antibiotic therapy may be indicated if **infection** of the deep tissues is **suspected**.¹⁸ Dilute chlorhexidine solution (0.05%) can be used daily to cleanse wounds; it is minimally cytotoxic and more bactericidal in the presence of cellular debris than is povidone-iodine solution.²¹ Prolonged contact of a stronger solution of chlorhexidine (0.5%) has been demonstrated to slow formation of granulation tissue and to hinder tissue healing.²²

Before grafting, bone beneath deep wounds should be examined radiographically for the presence of osteitis (which must be resolved) or sequestra (which must be removed). A large wound often develops healthy granulation tissue along its periphery before a sequestrum is visible radiographically. In our experience, grafting can be performed successfully along the periphery of such wounds. A second grafting procedure can then be performed in the center of the wound after the sequestrum is removed and healthy granulation tissue has developed.




Figure 1—Harvesting pinch grafts from a donor site. The split-thickness graft is harvested by severing the elevated cone of skin under the needle.

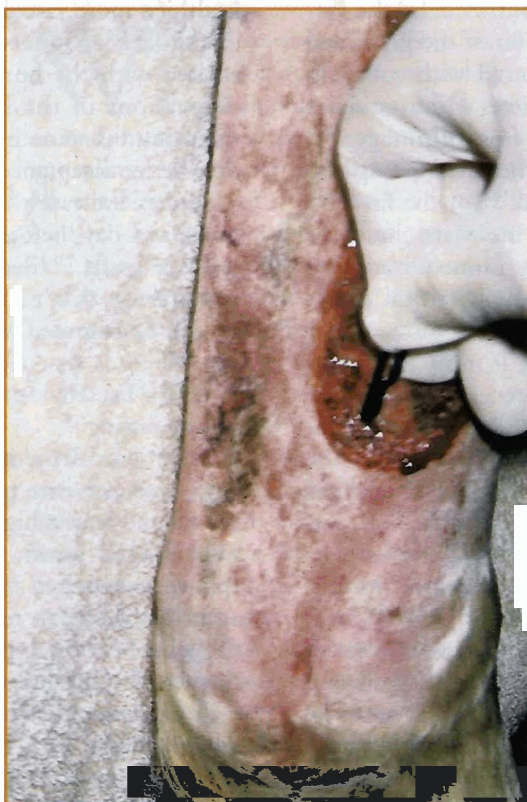

Figure 2—Implantation of pinch grafts into pockets (created by a No. 15 blade) in the granulation tissue of the recipient bed.

PREPARATION OF THE DONOR SITE

Selection of the donor site is dictated by the grafting technique to be used. A donor site should be easily accessible for procuring the graft or grafts. The most cosmetic sites for graft procurement may be regions of the neck covered by the mane, the ventral abdomen, or the ventral pectoral region. Other donor sites include the sternal region, the region caudal to the girth path, and the perineum.^{17,18} Cosmesis of the wound is best when the donor hair (color and texture) matches that adjacent to the graft site. Local anesthesia of the skin and possibly sedation of the horse are necessary for safe retrieval of the full-thickness donor skin.

Skin for island grafting can be obtained from the perineum after caudal epidural anesthesia.¹⁸ This donor site is particularly convenient for grafting a wound on a rear limb. Split-thickness grafts can only be harvested safely when the horse is anesthetized.

Regardless of the donor site chosen, it should be clipped (rather than shaved) to prevent damage to the epithelium. The site should be prepared with an antimicrobial scrub.¹⁸

TECHNIQUES Pinch Grafting

Pinch grafting is the technique of implanting small disks of skin (3 mm in diameter) into the granulation tissue of a wound.^{2,18,23} Pinch grafting is easily performed in the field. Grafts are procured by elevating the skin with forceps or a needle with a bent point and severing the elevated cone of skin at its base (Figure 1). The center of such a graft is nearly full-thickness and contains some hair follicles.

The graft is implanted into a pocket created in the granulation tissue by means of a No. 15 or No. 11 scalpel blade (Figure 2). The granulation tissue is stabbed obliquely with the blade to create a pocket 2 mm below the surface such that the opening of the pocket is proximal to the surface. The pockets are usually created in parallel rows at 1-cm intervals. Digital pressure should be applied to the pocket for 15 to 30 seconds to control hemorrhage, which may dislodge the grafts.

Insertion of grafts into the pockets can be tedious. A small thumb forceps, a blunted needle, or a No. 15 blade helps in implanting the grafts into the pockets. Grafts can be placed on a saline-soaked sterile sponge, or four to five grafts can be placed on the wound (where they are maintained by hydrostatic pressure) as the pockets are being created. This speeds implantation by minimizing repetitive steps. Immediately after insertion, moderate digital pressure for 15 to 30 seconds may be necessary to control hemorrhage and maintain the grafts in the pockets.

Because of hemorrhage, pocket creation and grafting of a wound should commence distally and progress proximally. Large wounds of the limb are best divided into proximal to distal thirds. Starting with the most distal section, pockets are created and grafts are implanted. After the distal section of the wound is grafted, that section is bandaged with a sterile nonadherent pad and sterile gauze roll before the next (more proximal) section is treated. Staged bandaging prevents loss of grafts if the horse moves or there is excessive hemorrhage. Although the bandage becomes blood-soaked, this technique helps

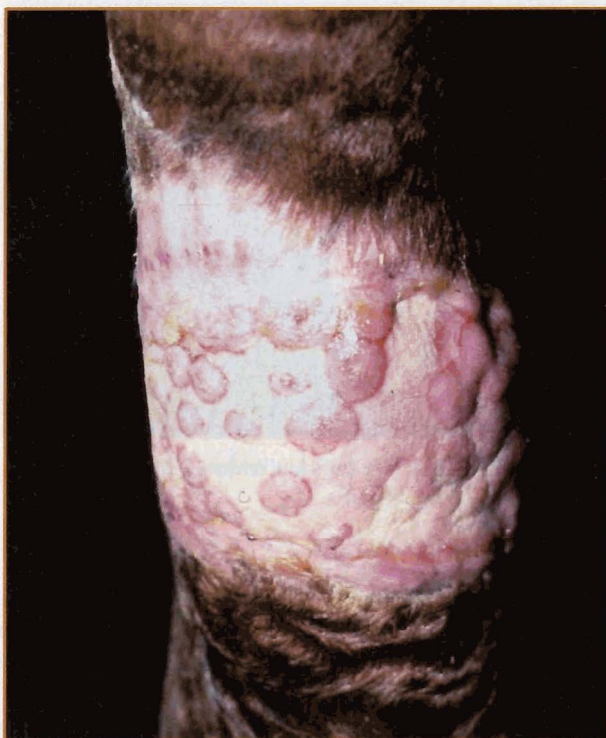

Figure 3—Advanced stage of epithelialization after pinch-graft implantation. The cobblestone appearance of divergent, sparse hair growth is cosmetically unacceptable to some clients.



Figure 4—Punch grafts obtained directly from the donor site (with the horse standing). Because this is a full-thickness graft, the subcutaneous tissue should be sharply excised before graft implantation.

prevent loss of grafts.

For pinch grafts, a 75% acceptance rate can be expected.¹⁷ This percentage is good and may be partially related to the pockets, which hold the graft in contact with the granulation tissue. The surface of the granulation pocket normally necroses during healing; epithelialization then proceeds circumferentially from the graft. Because pinch grafts are small, complete epithelialization may take a long time, especially if few grafts were implanted or there is a high percentage of graft loss.¹

An advantage of this grafting technique is that the donor-site defects are small and not completely full-thickness. They are thus usually left open to heal by second intention.

One disadvantage of pinch grafting is the difficulty in orienting the direction of hair growth because of the small donor-graft size. Because wounds heal primarily by epithelialization and the amount of hair follicles that survive is small, it may not be worthwhile to try to maintain the orientation of hair. Nevertheless, systematic grasping of the graft and maintaining it in this orientation while it is placed in its pockets may allow appropriate direction of hairs. If the hairs are directed proximally, they help to stabilize the graft and make it easier to

insert into the recipient bed. Despite careful orientation, hair growth may occur in multiple directions. This divergence of hair can help to cover the epithelial scar that develops between the islands of skin.

Once they are healed, wounds often have a cobblestone appearance (Figure 3). For owners of show horses, this may not be cosmetically acceptable.¹⁸

Punch Grafting

Punch grafting is similar to pinch grafting and can be readily performed in the field with the horse standing. Using a skin biopsy punch, circular plugs of skin are removed directly from the anesthetized donor site (Figure 4) or punched from a piece of skin that has been removed from the donor site (Figure 5). During harvesting from the ventral pectoral region, punch grafts are best placed on a saline-soaked sponge.¹⁸ Because punch grafts are full-thickness, subcutaneous tissue and fascia must be removed with a blade before the grafts are implanted.²⁰ It is easier to remove subcutaneous tissue from a section of skin before punches are harvested because removal from individual plugs is tedious.

A biopsy punch, usually 2 mm smaller than that used to obtain the donor graft, is used to create recipient sites

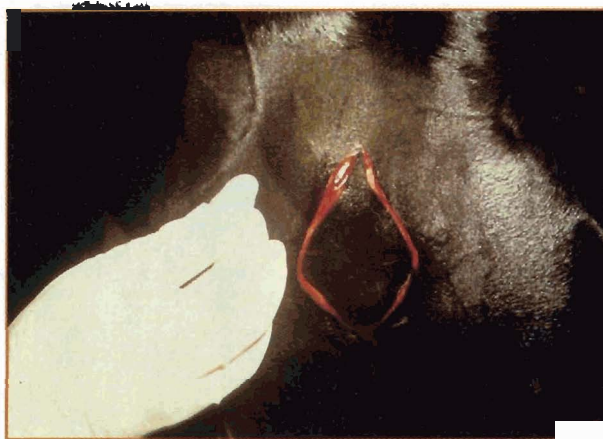


Figure 5—An elliptic piece of skin removed from the chest to create punch or tunnel grafts.

for the punch biopsies.² We use 8-mm biopsy punches for harvesting and 6-mm punches to create the recipient sites (Figure 6). Biopsy holes in the granulation tissue are placed at 5- to 15-mm intervals. Cotton-tipped applicators can be placed in a hole to aid in identifying the hole in the granulation tissue, which rapidly becomes obscured by hemorrhage⁶ (Figure 7).

A second approach to controlling hemorrhage after placement of punch sites is to bandage the recipient site

for several hours. The grafts can be applied directly from the donor site or can be stored in a refrigerator on saline-soaked gauzes during this period. Because some hair follicles are present, it may be beneficial to orient the graft so that hair growth is in a proper direction. If the wound is large, staged bandaging during the implantation process (as described for pinch grafting) may

prevent loss of grafts by precluding excessive hemorrhage or movement of the graft.

The donor graft sites can be closed with sutures or staples or can be left open to heal by second intention. If an elliptic piece of skin is removed to obtain the punch grafts, the donor site should be sutured.¹⁷ If punches are removed directly, the donor sites heal with multiple stellate scars.¹⁷ As with pinch grafting, the recipient site may develop an unc cosmetic cobblestone appearance. Nevertheless, hair coverage is more prominent with this technique.^{13,17,18} Studies have reported graft survival as high as 95% and epithelialization of the entire wound within 47 days.^{1,7,19,24-26}

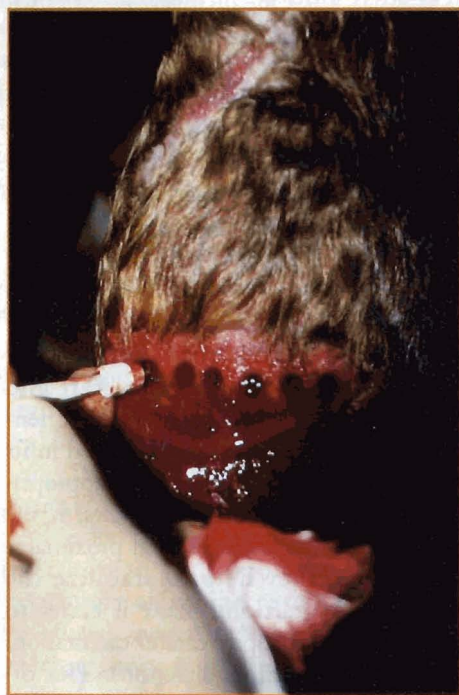

Figure 6—Creation of the recipient sites for donor punch grafts using a 6-mm skin biopsy punch.

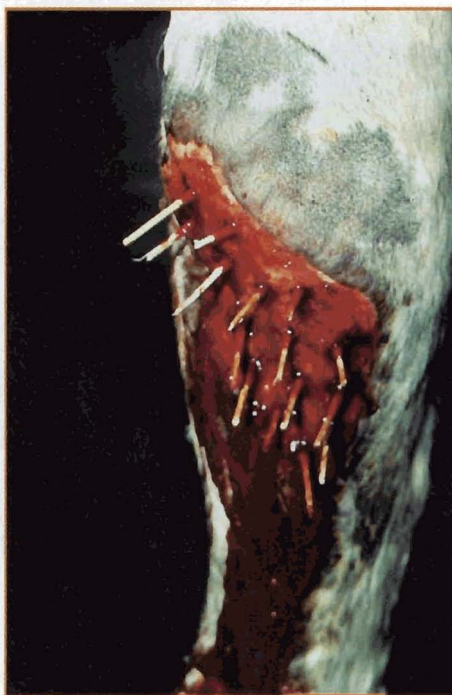

Figure 7—Sterile applicators placed in the recipient-site pouches to facilitate hemostasis and identification of the site (which is obscured by blood) in the granulation tissue.

Tunnel Grafting

Tunnel grafting requires

harvesting of full-thickness or split-thickness strips of skin that are 2 to 5 mm wide and slightly longer than the wound^{3,4,6,17,18,27} (Figure 8). Full-thickness skin is often used in field situations because split-thickness skin grafts are difficult to obtain without special equipment (e.g., free-hand knives or motorized dermatomes) and general anesthesia.¹⁸ To improve acceptance of the graft, subcutaneous fascia and fat should be sharply dissected from full-thickness donor skin.²⁰ Often, the easiest method of obtaining tunnel grafts is to remove a sheet of skin from the donor site. Strips of skin are then easily cut from the stretched and stabilized sheet¹⁸ (Figure 5). To minimize scarring, the donor site is sutured by primary closure.¹⁸

The grafts are implanted in tunnels created in the granulation tissue, which has been allowed to develop 4 to 8 mm above skin level.⁴ These tunnels are created via a cutting needle, a flattened Kirschner wire with a trocar point, a straight teat blade, or a malleable alligator forceps.^{3,4,14,27,28} An alligator forceps or a small tendon forceps is then used to grasp and pull the skin strip into the bed⁴ (Figure 9). To prevent vascular compromise of the granulation tissue, tunnel grafts should be placed no less than 1 cm apart.⁴

In one popular method used to implant tunnel grafts, adhesive tape (slightly longer than the graft) is placed on the haired side of the graft to minimize graft rotation.^{3,28} The graft and tape are then threaded through the eye of a 10- to 12-cm, half-curved or straight

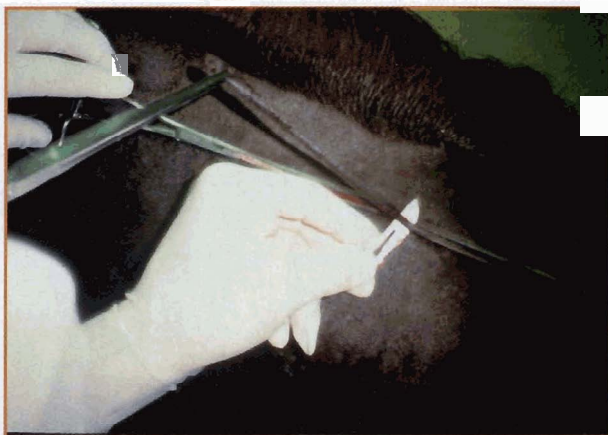


Figure 8—Creation of a tunnel graft from skin along the neck.

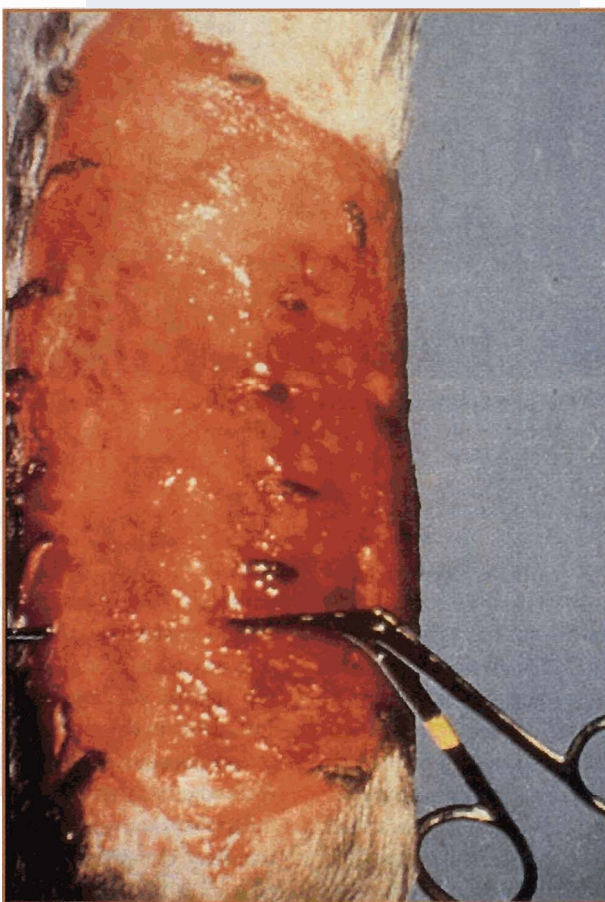


Figure 9—Creation of a tunnel in the recipient granulation tissue and implantation of a tunnel graft using a tendon forceps to pull the grafted tissue through the wound bed.

cutting needle.⁴ The needle and graft are inserted through the granulation tissue 5 mm below the surface. The haired side should be facing outward, and the hair should be oriented in the proper direction.⁴

Because the needle is often smaller than the wound length, multiple small strips of grafts are used or a longer graft is placed over the width of the wound by a two- or three-step passage of the needle.¹⁷ The needle reenters the point of exit for the second and third bite. Tunnel grafts inserted into a wound on a limb should be placed circumferentially because of the increased difficulty in placing the grafts in the proximodistal direction.

When tape is used to facilitate implantation of the graft, the graft may become dislodged, especially if the tape is removed immediately after insertion or later with excision of overlying granulation tissue.^{3,28} Attaching the tape to the graft can be tedious and can increase surgical time.²⁸ Such attachment is unnecessary if an alligator forceps is used.¹⁷

In some cases, tunnels can be created with the horse standing; however, because slight movement may destroy the tunnel, short-term general anesthesia may be required.¹⁸ In our opinion, general anesthesia facilitates placement of grafts.

To minimize anesthesia time, a full-thickness sheet of tissue can be harvested while the horse is standing.

The sheet is cut into strips, stored on sponges soaked with physiologic saline, and then placed into the granulation bed after the horse is anesthetized. The ends of

the graft are then sutured, stapled, or glued to the edge of the wound for additional security.¹⁷ Graft survival is enhanced by exposing the tunnel grafts away from the overlying granulation tissue 6 to 10 days after implantation.²⁸ Because most failures can be attributed to accidental removal of the graft or failure to expose the graft, the surgeon who placed the grafts should remove the overlying granulation tissue.²⁸

Tunnel grafts are useful for coverage of sites that are hard to bandage or highly mobile (e.g., the dorsal surface of the hock) because the graft is restrained by the overlying granulation tissue.^{2,17} (Figure 10). Survival rates of 80% have been reported for tunnel grafts, and cosmesis of the healed wound is generally better than that of similar wounds that are left ungrafted.²⁸ Because a tunnel graft is a type of island graft, the wound heals largely by epithelialization.

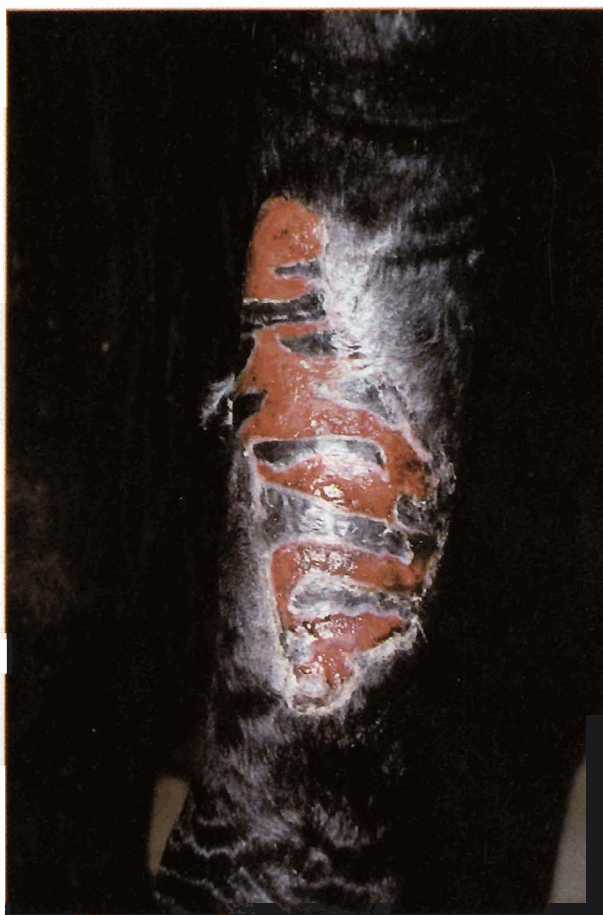

Figure 10—Epithelialization after tunnel grafting of a wound. (Courtesy of Dr. D. G. Wilson, Department of Surgical Sciences, College of Veterinary Medicine, University of Wisconsin)

Sheet Grafting

Sheet grafting produces better cosmesis at the recipient site than does island grafting.¹⁸ Because a sheet graft covers the entire wound, it is less effective in allowing the exudate to escape; this can interfere with the ability of the graft to revascularize.¹⁸ Acceptance is good only if the recipient bed is uncontaminated, at an immobile site, and fresh or composed of immature granulation tissue.³ Horses with wounds that contain mature granulation tissue are thus poor candidates for this type of skin grafting.¹

Full-thickness sheet grafting is easy to perform, requires slight expertise, and does not require expensive equipment. Most grafts can be obtained from a standing, sedated horse via regional or local anesthesia. The most suitable area for obtaining full-thickness grafts is the cranial pectoral region, where loose skin is most abundant.^{17,29} An elliptic section of skin can be ob-

tained from the recipient site and trimmed to fit the wound. Alternatively, a template of the wound can be made from sterilized paper and used to trace the recipient bed to ensure that the graft is the correct size.¹⁷

Once excised, full-thickness grafts undergo primary shrinkage due to recoil of elastic fibers in the deep dermal layers.¹⁷ To allow for primary shrinkage, the graft should be cut slightly larger than the template.^{30,31} If the section of donor skin required to cover the wound would be so large that the donor site could not be sutured, it may be necessary to transport the horse to a fully equipped practice; a split-thickness graft (which does not require closure of the donor site) can be obtained via dermatome equipment with the horse anesthetized.

To improve acceptance of a full-thickness sheet graft by the recipient bed, it is generally necessary to (1) remove the subcutaneous tissue from the graft, (2) establish hemostasis of the

wound, and (3) stabilize the graft. The subcutaneous tissue should be carefully excised with a scalpel to prevent crushing or scraping of the dermis. Hemostasis is critical to prevent the graft from separating from the recipient bed.³

To prevent contraction, the graft should be fixed to the edge of the wound by means of sutures, staples, or cyanoacrylate glue.¹⁸ Caution is necessary to avoid occluding the small dermal vessels by overstretching the skin.³² It may be necessary to inject local anesthetic into the edge of the wound if the graft is to be sutured or stapled with the horse standing. Interrupted sutures may be required to attach the center of the graft to the recipient bed. If possible, the grafted site should be bandaged to maintain the graft against the recipient bed.

Full-thickness grafts have a relatively low rate of acceptance because revascularization of these grafts is more difficult and exudate may become trapped beneath the

graft.^{20,30,33-35} Full-thickness grafting, however, gives the healed wound a better cosmetic appearance because the graft contains all of the properties of the surrounding skin, provides maximum hair growth, and can withstand pressure and friction.¹⁷

Mesh Grafting

Mesh grafts are multiple, uniform fenestrations that are created by hand- or mesh-grafting instruments. These grafts allow fluid to drain, topically applied medication to reach the granulation bed, and the graft to conform better to irregular surfaces^{17,18,36,37} (Figure 11). The meshing of grafts may improve acceptance and allow a small piece of skin to be expanded to cover a large recipient site.²

Meshing a large graft by hand is tedious. Meshing can be facilitated by wrapping the graft several times around a flat strip of sterilized cardboard, x-ray film, or plastic.^{2,17,18} Straight cuts are then made with sharp scissors at regular intervals halfway through the skin and cardboard on both sides.³⁸

The time required for the wound to epithelialize completely depends on the expansion ratio of the graft. A graft with a ratio of 9:1 can cover a wound that is nine times larger than the original width of the graft; however, the large areas of the wound within the fenestrations must heal by epithelialization, which increases the time of healing and scar formation. A graft with a 3:1 expansion ratio allows more rapid healing; less epithelialization is necessary to heal the wound.^{6,17,36}

POSTOPERATIVE CARE

Acceptance of a graft depends on strict attention to the postoperative care of the wound. Grafts fail when revascularization is obstructed, infection occurs, or the graft is separated from its bed.^{1,2,6} During the first 4 to 12 days (when the graft is revascularizing and is fixed to the recipient bed by fibrin), the graft should be protected from

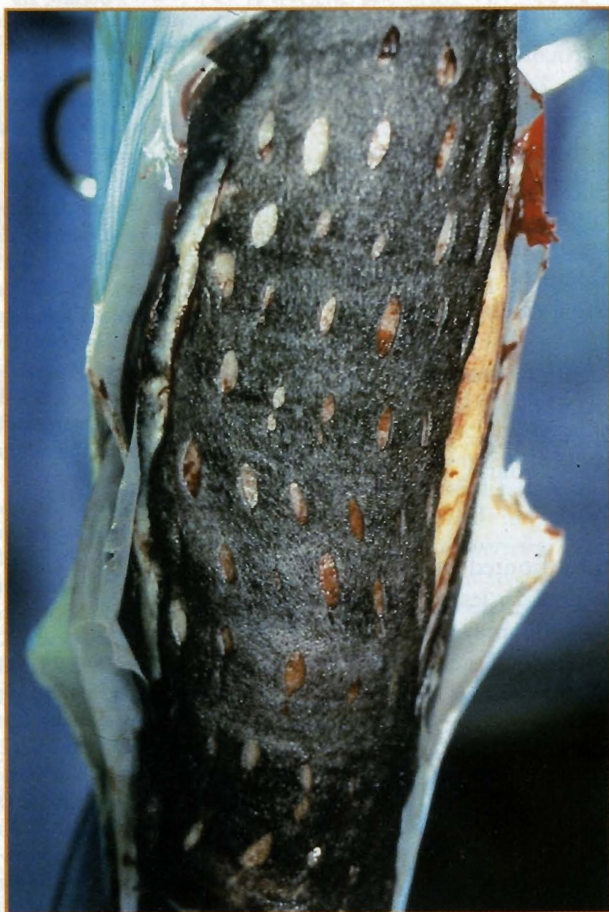

Figure 11—A full-thickness, hand-meshed sheet graft attached with sutures to a wound on a limb.

the environment, if possible, by a snug and well-padded bandage.^{4,18} After this period, continued support of the grafted site with a bandage may lessen edema and decrease the possibility of self-mutilation.⁶ Because many areas on a horse are difficult to bandage, a tie-over dressing can be used to secure a nonadherent sterile dressing directly over the graft (e.g., a large wound on the back).^{6,19}

In our opinion, it is beneficial to change the bandage every 2 to 3 days. Frequent changes allow a cleaner environment for the grafted site and quick recognition of infection. The bandage must be carefully removed at each changing. Soaking the bandage with saline before removal may help loosen fibrous attachments between the graft and bandage. Discharge should be swabbed (not wiped) with gauze that is moistened with a dilute antimicrobial agent.

In our experience, a 0.05% solution of chlorhexidine diacetate is a useful antimicrobial agent; it is not systemically absorbed, causes no systemic toxicosis, is not inactivated by organic matter, and is superior to povidone-iodine in killing *Staphylococcus aureus*.³⁹ At this concentration, chlorhexidine diacetate has significantly more bactericidal activity than does 0.1% or 1.0% povidone-iodine or physiologic saline.⁴⁰ Unlike povidone-iodine, chlorhexidine diacetate (at 0.005% or 0.05%) has residual effects 6 hours after irrigation.⁴⁰

Systemic administration of broad-spectrum antibiotics for 5 days after skin grafting, especially after grafting fresh wounds, may be beneficial.¹⁹ In our experience, however, daily application of topical antimicrobials is more effective than systemic treatment in maintaining the health of the wound and allowing graft acceptance. We most often use 1.0% water-miscible, silver sulfadiazine cream; this agent is effective against most gram-positive and gram-negative organisms and promotes rapid epithelialization.^{41,42}

If excessive granulation tissue develops before complete epithelialization, topical corticosteroid ointments limit the formation of such tissue by inhibiting lysosomal activity and fibroblastic proliferation.^{38,43,44} Application of corticosteroids to the wound suppresses excessive proliferation of granulation tissue without clinically hindering the rate of epithelialization.^{38,43-45}

For horses that disturb the graft or donor site by chewing, antichewing products can be placed on the bandages. Cross-tying or applying a cradle may be necessary to prevent self-mutilation.

Regardless of the grafting technique used, failure of graft acceptance sometimes occurs and necessitates multiple grafting procedures. In most cases, persistence in regrafting results in healing of the wound.

SUMMARY

Equine practitioners are often confronted with horses that have large, granulating wounds. To lessen healing time and improve the cosmetic outcome, skin grafts can be performed in the field. Pinch, punch, tunnel, and full-thickness sheet grafts can be used. A successful outcome is obtained if the wound is properly prepared and carefully treated after grafting.

ACKNOWLEDGMENTS

The authors thank Steve Swaim, DVM, MS, John Schumacher, DVM, MS, and Mr. Fred Lux for their assistance in the preparation of this article.

About the Authors

Drs. Carson-Dunkerley and Hanson are affiliated with the Department of Large Animal Surgery and Medicine, College of Veterinary Medicine, Auburn University, Auburn, Alabama. Dr. Hanson is a Diplomate of the American College of Veterinary Surgeons.

REFERENCES

- French DA, Fretz PB: Treatment of equine leg wounds using skin grafts: Thirty-five cases, 1975-1988. *Can Vet J* 31:761-765, 1990.
- Vacek JF, Honnas CM, Ford TS, Schumacher J: The principles of equine grafting. *Vet Med* 87:690-695, 1992.
- Blackford JT: Skin grafting in horses. *Equine Pract* 15(9): 25-30, 1993.
- Wilson DG: Application of skin grafting in large animals, in Lindsay WA (ed): *Problems in Veterinary Medicine*, ed 2. Philadelphia, JB Lippincott Co, 1990, pp 442-462.
- Swaim SF: Skin grafts, in Swaim SF (ed): *Surgery of Traumatized Skin: Management and Reconstruction in the Dog and Cat*. Philadelphia, WB Saunders Co, 1980, pp 423-476.
- Caron JP: Skin grafting, in Auer JA (ed): *Equine Surgery*.

- Philadelphia, WB Saunders Co, 1992, pp 256-272.
- Boyd CL: Equine skin autotransplants for wound healing. *JAVMA* 151:1618-1624, 1967.
- Ford TS, Schumacher J, Brumbaugh GW, Honnas CM: Effects of split-thickness and full-thickness skin grafts on secondary graft contraction in horses. *Am J Vet Res* 53(9): 1572-1574, 1992.
- Lees MJ, Fretz PB, Bailey JV, Jacobs KA: Principles of grafting. *Compend Contin Educ Pract Vet* 11(8):954-961, 1989.
- Swaim SF: Wound healing, in Swaim SF (ed): *Surgery of Traumatized Skin: Management and Reconstruction in the Dog and Cat*. Philadelphia, WB Saunders Co, 1980, pp 70-115.
- Booth L: Equine wound reconstruction using free skin grafting. *Calif Vet* 45(6):13-16, 1991.
- Argenta LC, Kingman RO: Skin grafting, in Epstein E (ed): *Skin Surgery*. Philadelphia, WB Saunders Co, 1987, pp 129-139.
- Converse JM, Smahel J, Ballantyne DL, et al: Inosculation of vessels of skin graft and host bed: A fortuitous encounter. *Br J Plast Surg* 29:274-282, 1975.
- Sebben JE: Surgical antiseptics. *J Am Acad Dermatol* 9: 759-765, 1983.
- Bjorck G, Twisselman K: Tunnel skin grafting in the equine species. *Proc AAEP* 17:313-321, 1971.
- Stashak TS: Principles of free skin grafting, in Stashak TS (ed): *Equine Wound Management*. Philadelphia, Lea & Febiger, 1991, pp 218-237.
- Schumacher J, Hanselka DV: Skin grafting of the horse. *Vet Clin North Am Equine Pract* 5:591-614, 1989.
- Vacek JR, Honnas CM, Ford TS, Schumacher J: Skin grafting techniques in horses. *Vet Med* 87:696-703, 1992.
- Lindsay WA: Step-by-step instructions for equine skin grafting techniques. *Vet Med* 83:598-609, 1988.
- Argenta LC, Dingman RO: Skin grafting, in Epstein E (ed): *Skin Surgery*. Philadelphia, WB Saunders Co, 1987, pp 129-139.
- Swaim SF: Bandages and topical agents. *Vet Clin North Am Small Anim Pract* 20:47-65, 1990.
- Lee AH, Swaim SF, McGuire JA, et al: Effects of chlorhexidine diacetate, povidone-iodine, and polyhydroxydine on wound healing in dogs. *JAAHA* 24(1):77-84, 1988.
- Mackay-Smith MP, Marks D: A skin grafting technique for horses. *JAVMA* 152:1633-1637, 1968.
- Schumacher J, Gordon WB, Honnas GM, Tarpley RJ: Kinetics of healing of grafted and nongrafted wounds on the distal portion of the forelimbs of horses. *Am J Vet Res* 53(9):1568-1571, 1992.
- Stashak TS: Skin grafting in horses. *Vet Clin North Am Equine Pract* 6:215-225, 1984.
- Boyd CL, Hanselka DV: A skin punch techniques for equine skin grafting. *JAVMA* 158(1):82-88, 1971.
- Swaim SF, Lee AH, Newton JC, McGuire JA: Evaluation of strip skin grafts in dogs. *JAAHA* 23:155-162, 1987.
- Lees MJ, Andrews GC, Bailey JV, Fretz PB: Tunnel grafting of equine wounds. *Compend Contin Educ Pract Vet* 11(8): 962-971, 1989.
- Hanselka DV: Inexpensive mesh grafting technique in the horse. *Proc AAEP* 21:191-196, 1975.
- Ross GE: Clinical canine skin grafting. *JAVMA* 153: 1759-1765, 1986.
- Rudolph R: Inhibition of myofibroblasts by skin grafts. *Plast Reconstr Surg* 63:473-480, 1979.

32. Davis JS, Trout HF: Origin and development of the blood supply of whole thickness skin grafts: An experimental study. *Ann Surg* 82:871-879, 1925.
 33. Bell RC: Types of autografts, in Bell RC (ed): *The Use of Skin Grafts*. New York, Oxford University Press, 1973, pp 5-17.
 34. Cason JS: Skin grafting and diagnosis of depth of burning, in Cason JS (ed): *Treatment of Burns*. London, England, Chapman and Hall, 1981, pp 108-141.
 35. Hogle R, Kingrey BW, Jensen EC: Skin grafting in the horse. *JAVMA* 135:165-170, 1959.
 36. Hanselka DV: Use of autogenous mesh grafts in equine wound management. *JAVMA* 164:35-41, 1974.
 37. Swaim SF: Principles of mesh grafting. *Compend Contin Educ Pract Vet* 4(3):194-200, 1982.
 38. Baker BL, Whitaker WL: Interference with wound healing by the local action of adrenocorticoid steroids. *Endocrinology* 46:544-551, 1950.
 39. Amber EI, Henderson RA, Swaim SF, et al: A comparison of antimicrobial efficacy and tissue reaction of four antiseptics on canine wounds. *Vet Surg* 12:63-68, 1983.
 40. Sanchez IR, Swaim SF, Nusbaum KE, et al: Effects of chlorhexidine diacetate and povidone-iodine on wound healing in dogs. *Vet Surg* 17:291-295, 1988.
 41. Eaglstein WH, Mertz PM: Effect of topical medications on the rate of repair of superficial wounds, in Dineen P, Kildrick-Smith G (eds): *The Surgical Wound*. Philadelphia, Lea & Febiger, 1981, p 150.
 42. Kjolseth D, Frank JM, Barker JH, et al: Comparison of the effects of commonly used wound agents on epithelialization and neovascularization. *J Am Coll Surg* 179:305-312, 1994.
 43. Ehrlich HP, Hunt TX: The effects of cortisone and anabolic steroids on the tensile strength of healing wounds. *Ann Surg* 170:203-206, 1969.
 44. Howes EL, Plotz CM, Blunt JW, et al: Retardation of wound healing by cortisone. *Surgery* 28:177-181, 1950.
 45. Blackford JT: The effects of an antimicrobial-glucocorticosteroid ointment on granulating lower-leg wounds in the horse. *25th Annu Surg Forum Am Coll Vet Surg*:59, 1990.
- d. sheet
 - e. all of the above
3. The success of grafting depends on
 - a. adherence of the graft to the bed.
 - b. plasmatic imbibition.
 - c. revascularization.
 - d. organization of fibrinous adhesions.
 - e. all of the above
 4. Which of the following statements concerning the recipient site is true?
 - a. Tissue that is capable of accepting a graft is firm, red, vascular, and free of purulent discharge.
 - b. Excision of chronic, proliferative granulation tissue is never necessary before grafting.
 - c. Application of grafts to chronic wounds does not result in graft acceptance.
 - d. *Escherichia coli* is the bacterium that is most destructive to grafts.
 - e. Therapeutic concentrations of antimicrobial drugs at the recipient site to manage infection can always be achieved by systemic treatment.
 5. Which of the following statements concerning preparation of donor sites is false?
 - a. Site selection is dictated by the grafting technique.
 - b. The color and texture of the donor hair should match the graft site.
 - c. Sites include the pectoral area, neck, ventral midline, caudal sternal region, and perineum.
 - d. Sites should be clipped, rather than shaved, to prevent damage to the epithelium.
 - e. Aseptic preparation of the site is unnecessary.
 6. Which of the following statements concerning pinch grafting is true?
 - a. It uses full-thickness plugs of skin.
 - b. It requires suturing of donor-site defects.
 - c. It places split-thickness skin plugs into pockets made in the recipient site.
 - d. It commonly results in low graft acceptance.
 - e. It is very cosmetic and produces thick hair growth.
 7. Which of the following statements concerning punch grafting is true?
 - a. It uses full-thickness plugs of skin.
 - b. It can only be performed on recumbent horses.
 - c. It produces no hair growth at the recipient site.
 - d. It is the most cosmetic grafting procedure.
 - e. It places grafts into pockets made in the recipient site.
 8. Which of the following statements concerning tunnel grafting is true?
 - a. It uses circular plugs of skin.
 - b. It is useful on wounds that are in highly mobile regions.

ARTICLE #6 REVIEW QUESTIONS

The article you have read qualifies for 1/2 hour of Continuing Education Credit from the Auburn University College of Veterinary Medicine. Choose only the one best answer to each of the following questions; then mark your answers on the test form inserted in *The Compendium*.

1. Skin grafts are classified on the basis of
 - a. the source.
 - b. thickness.
 - c. blood supply.
 - d. thickness and blood supply.
 - e. all of the above
2. Which of the following types of free grafts are practical for field grafting?
 - a. pinch
 - b. punch
 - c. tunnel