



nonstrangulating disorders, such as impaction. As gas accumulates and the bowel becomes distended, the bowel wall is stretched and the horse feels pain. This is one of the most difficult types of pain to control. The horse may develop visible distention of the flanks, or distention may be palpable per rectum. The horse's metabolic status and clinicopathologic findings depend on the severity of the condition. However, once distention begins to increase, obstructive shock and respiratory compromise progress rapidly.

Horses with mild-to-moderate tympany frequently respond to analgesics and fluid therapy. Resolution of

signs in early stages of the condition depends on maintaining colonic motility so that the gas can be expelled. This is accomplished by controlling pain to minimize sympathetic inhibition of motility. Oral administration of mineral oil helps minimize absorption and aids excretion of any offending material. As distention becomes excessive, trocarization may be required to slow the course of events until the process subsides. This should be performed via the right and/or left flank, depending on the location of the distention. Gas distention and atony may predispose to colon displacement or volvulus as well.

Diseases of the Small Colon

R. REID HANSON

Diagnostic and Therapeutic Considerations

The small colon is a caudal continuation of the transverse colon to the left of the mesenteric root and occupies the caudal left quadrant of the abdomen in close proximity with the jejunum. The small colon has wide, muscular mesenteric and antimesenteric bands and coarse sacculations.⁹⁰² The small colon is approximately 4 m (13 feet) long and has a diameter of 6 to 8 cm (2.5 to 3 inches). The mesocolon is longest in the center with a length of 80 to 100 cm (31 to 39 inches). The small colon is attached proximally to the duodenum by the short pelvic duodenocolic fold and distally continues at the pelvic inlet as the peritoneal rectum, which enlarges to form the ampulla recti.

The main blood supply to the small colon is from the left colic artery and the cranial rectal artery, which are branches of the caudal mesenteric artery (Fig. 10-173). The left colic artery supplies the proximal 75% of the small colon and branches into four to eight anastomosing arteries that divide to become marginal and terminal arteries.⁹⁰³⁻⁹⁰⁵ The cranial rectal artery courses caudally in the small colon mesentery to supply the distal 25% of the small colon with similar marginal and terminal arteries. The joining anastomosing arteries form the marginal artery 1 to 2 cm (0.5 to 0.75 inch) dorsal to the bowel serosal surface, which is obscured from view by fat in the mesocolon. The small colon is quite evident during transrectal palpation by the presence of fecal balls in the lumen and the thick antimesenteric taenial band. The proximal and distal 30 cm (11 inches) of the small colon cannot be exteriorized through a ventral midline surgical incision.

Horses with small colon obstruction usually exhibit mild colic and progressive abdominal distention.

American miniature horses, Arabians, and ponies are more predisposed to diseases of the small colon than other breeds. Mares and horses greater than 15 years old are more likely to be affected with diseases of the small colon, whereas horses less than 5 years old are less likely to be affected. Failure to pass feces can be an important part of the history, leading the clinician to suspect a lesion of the small colon. Dehydration typically is not marked, and vital signs often are within the normal range. Volvulus or vascular accidents involving the small colon have a more abrupt onset and rapid deterioration in vital parameters.⁹⁰² Survival rates for horses with colic have been significantly higher for small colon than for small intestine and large colon disorders.⁹⁰⁶

Simple intraluminal obstruction of the small colon may be caused by foreign material, ingesta, meconium, fibrous material, and enteroliths.^{907,908} Stricture and intussusception of the small colon occur but are rare. Extraluminal obstruction attributable to intramural hemorrhage, ovarian strangulation, or volvulus can also cause small colon obstruction. Fibrous foreign bodies, enteroliths, phytobezoars, trichobezoars, and phytoconglobates are managed successfully by colotomy.

Focal intraluminal obstructions of the small colon generally require a colotomy through the antimesenteric taenial band. This method results in a quicker completion of the colotomy; easier, more accurate apposition; and less hemorrhage and inflammation than those performed adjacent to the band.^{902,909,910} Closure of the mucosa as a separate layer facilitates seromuscular closure but does not affect the postoperative healing response or lumen diameter in normal horses.^{902,910}

Resection and anastomosis is required for conditions causing strangulating obstruction of the small colon. The passage of solid fecal balls through a relatively narrow lumen diameter associated with increased intraluminal

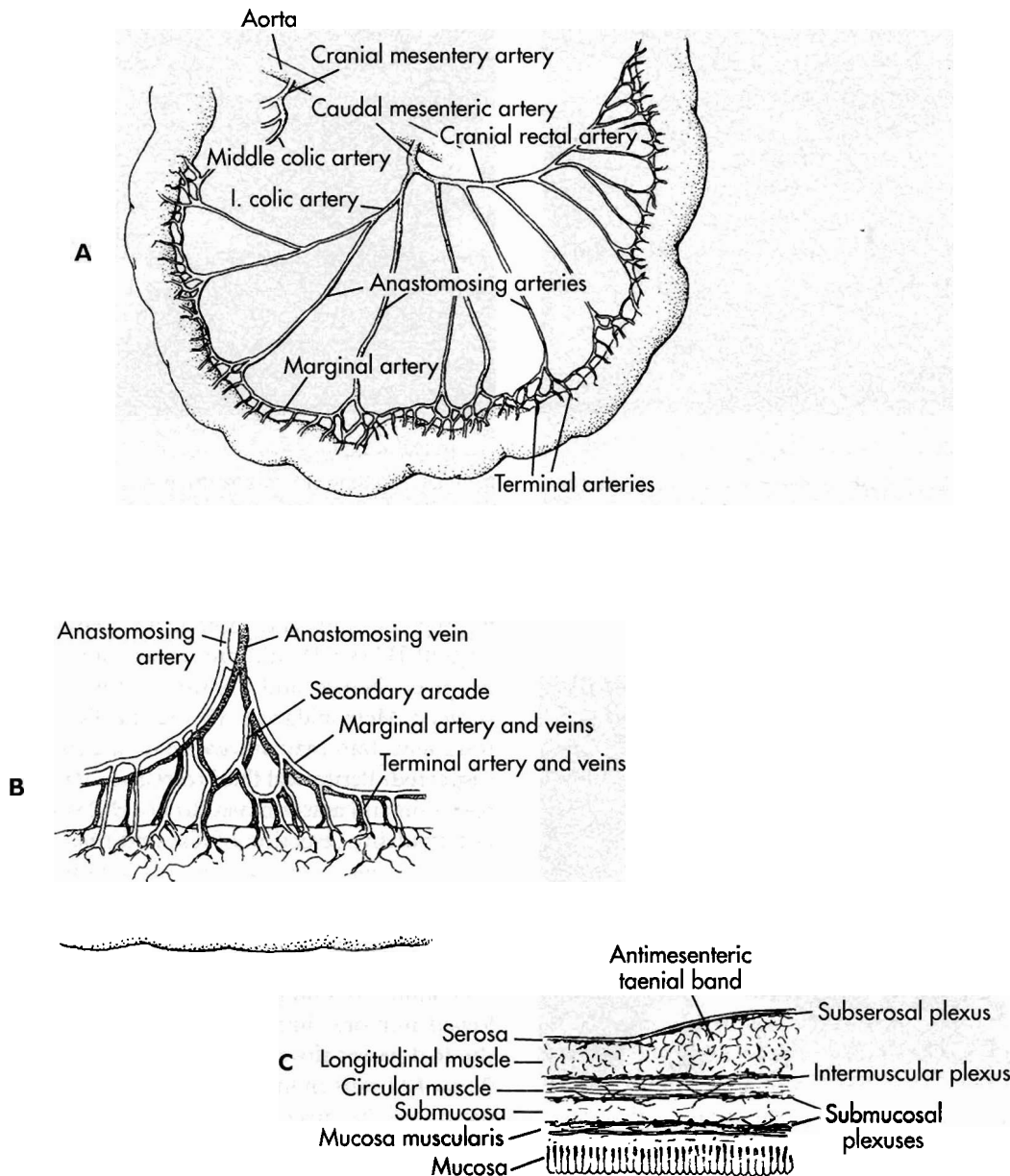


Fig. 10-173 A, Diagram of the arterial supply to the equine small colon showing the branching of the anastomosing arteries from the left colic and cranial rectal artery to form marginal arteries just dorsal to the mesenteric taenial band. B, Secondary arcades are present only where the anastomosing arteries split to form the marginal arteries. C, From the marginal arteries arise terminal arteries, which enter the small colon wall and give rise to a subserosal, an intermuscular, and a submucosal plexus with frequent anastomoses between them.

(Redrawn from Archer RM, et al: *Am J Vet Res* 50:894-895, 1989.)

bacterial concentrations, particularly anaerobic organisms, strong muscular activity, and increased tissue collagenase activity will delay the healing process.^{902,911} The preferred technique is a two-layer hand-sewn method including a simple-interrupted suture pattern that excludes mucosa oversewn with a continuous Cushings suture (Fig. 10-174). This method produces significantly larger lumen diameters, better anastomotic healing, and

minimal intraabdominal adhesion formation compared with end-to-end triangulated rows of stainless steel staples or other methods.⁹¹²⁻⁹¹⁴ Extensive mesocolic adhesions occur with stapled anastomoses and single-layer closures. Complications that occur with single- and double-layer inverting methods of small colon anastomosis include anastomotic leakage and stenosis, respectively (Figs. 10-175 and 10-176). Peritoneal soiling, especially

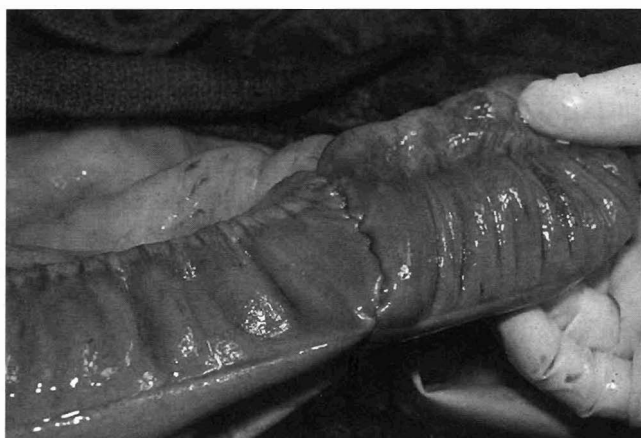

Fig. 10-174 A two-layer hand-sewn anastomosis with a simple-interrupted suture pattern that excludes the mucosa oversewn with a continuous Cushings suture. This technique can be used for resection and anastomosis of the small colon because it provides a strong seal of the intestine without excessively compromising the bowel lumen.

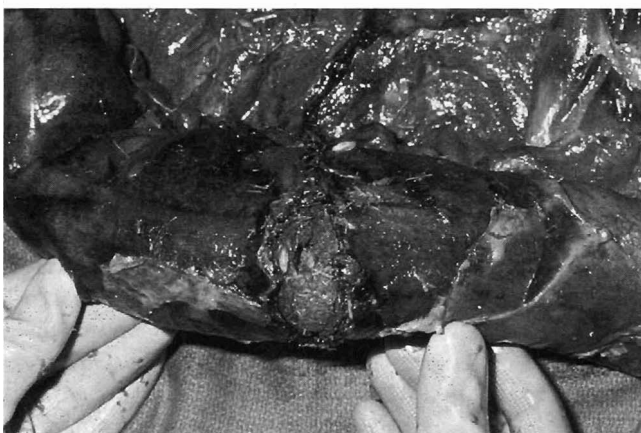

Fig. 10-175 Dehiscence of a small colon anastomosis resulting from inadequate strength of the anastomosis during the immediate postoperative period. A one-layer simple-interrupted technique was used to maintain a large lumen diameter.

with particulate matter, should be limited. Copious, continuous lavage and use of appropriate serosal protection can limit contamination, even when the bowel cannot be completely exteriorized. After the anastomosis has been completed, the large colon should be evacuated via a pelvic flexure colotomy to decrease the amount of ingesta that must pass through the rectum during the first 48 hours. This procedure lessens the chances of impaction, mucosal dissection, or severe contamination. The concentration of bacteria, particularly anaerobic species, increases in an aboral direction, and contamination of the surgical field with pathogenic bacteria may occur.

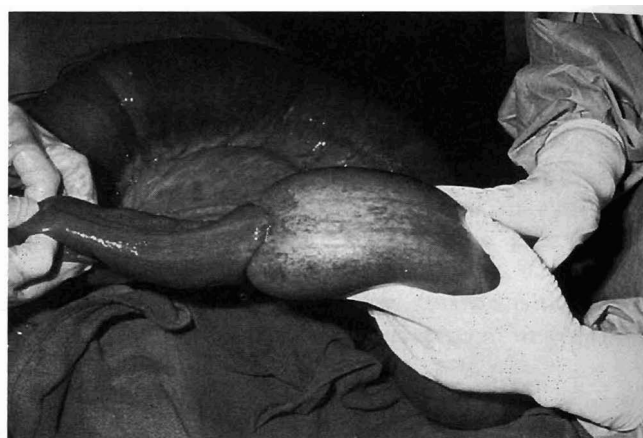


Fig. 10-176 Obstruction of a small colon anastomosis with fecal material, resulting from excessive inversion of the tissue layers in the closure. A two-layer inverting technique was used.

Broad-spectrum antibiotics such as gentamicin 4.4 mg/kg IV bid and potassium penicillin 22,000 to 44,000 IU/kg IV qid are usually sufficient and should be given before and continued for 3 to 5 days after surgery. Metronidazole 15 mg/kg PO qid is not given routinely, but may be useful if anaerobic infection is suspected. Peritoneal fluid responses after uncomplicated resection and anastomosis do not differ from procedures not involving resection of diseased tissue.⁹¹⁴

Diseases with Physical Causes

MECONIUM IMPACTION

Meconium is composed of intestinal secretions, swallowed amniotic fluid, and other cellular debris. Normally the foal passes this material via peristalsis within the first 24 to 48 hours of life. The firm and sometimes tenacious nature of the meconium adds to the effort required to pass it through the distal rectum and anus. Predisposing factors for meconium impactions include asphyxiation or other intestinal disease and lack of appropriate colostral intake. The narrow pelvic canal in male foals can be a contributing factor.

Clinical Signs

Colic becomes evident as the foal's abdomen begins to distend proximal to the meconium impaction. Tenesmus associated with repeated efforts to defecate are usually present before the onset of abdominal pain. In association with the abdominal press, there may be eversion of the rectal mucosa and dribbling of urine from the urachus.

Diagnosis

Diagnosis is based on the clinical signs of tenesmus associated with progressive abdominal enlargement in a

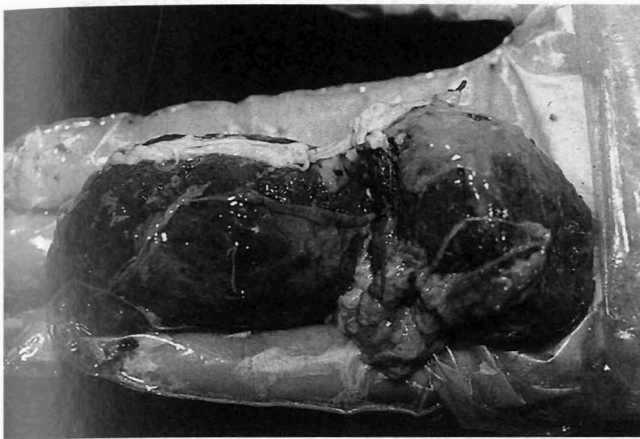

Fig. 10-177 Meconium impaction in a 2-day-old foal. The meconium is firm and covered in mucus, indicating that the mass had been lodged in the distal small colon for an extended period.

newborn foal. Digital rectal evaluation may reveal the impaction (Fig. 10-177). If no meconium is encountered by digital palpation of the rectum, a lateral abdominal radiograph may reveal a more proximal fecal material impaction associated with gas and fluid build-up (Fig. 10-178). Meconium impactions must be distinguished from other forms of intestinal obstruction, such as atresia coli. The results of peritoneal fluid analysis are usually within normal limits. Differential diagnosis includes ruptured bladder, urethral obstruction with straining, atresia coli, and other causes of small colon obstruction (e.g., foreign body, sand, and ovarian ligament strangulation).

Treatment

Treatment varies with the severity and site of impaction and the duration of clinical signs. Enemas with mild soap or dioctyl sodium succinate (DSS) in warm water (15 mL of 5% DSS diluted in 1 L of water) can be administered via soft tubing. Repeated use of a commercial phosphate-based product should be judicious. It is important to note that even dilute solutions of DSS may be irritating to the rectal mucosa.

Laxative therapy given via nasogastric intubation can be helpful. Common choices include mineral oil 200 to 400 mL, DSS 15 mL of a 5% solution diluted in water, or linseed oil 15 to 20 mL. Exercise will stimulate intestinal motility. Intravenous fluid therapy is helpful in reducing uncomplicated but long-standing meconium or small colon impactions. In an otherwise healthy foal, isotonic fluids are infused at a rate that exceeds maintenance

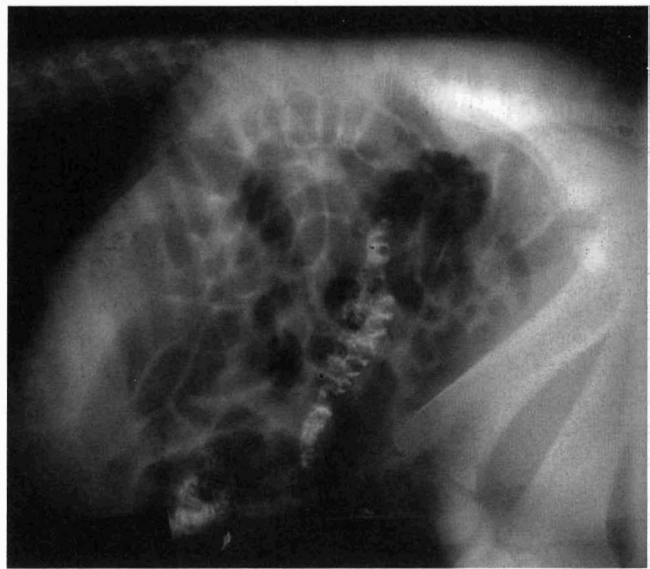

Fig. 10-178 Lateral abdominal radiograph of a 3-day-old foal with meconium impaction. A barium enema had been instilled to better delineate the impacted meconium. Extensive accumulation of gas in the large colon and proximal small colon is evident and accounts for the abdominal pain present in this foal.

requirements, in an effect to increase intraluminal fluid content.

Enemas with 4% solution of *N*-acetylcysteine have been successfully used in the foal for meconium impaction. This substance cleaves the disulfide bonds in the mucoprotein molecules and decreases the tenacity of the retained meconium. A size 30 Foley French catheter with a 30 mL bulb is inserted approximately 2.5 to 5 cm (1 to 2 inches) into the rectum. The balloon on the end of the Foley catheter is gradually inflated until the rectum is occluded; if this causes the foal pain, air is withdrawn from the balloon. Four to 8 oz of 4% acetylcysteine is slowly administered in the rectum. The Foley will ensure retention of the acetylcysteine. The enema may be repeated 1 hour later with a larger volume if a higher meconium retention is suspected or likely or meconium is not passed. In a 40 kg (88 lb) foal, approximately 24 to 30 oz are needed to reach the transverse colon. The use of acetylcysteine has been 100% successful in one retrospective study of 20 foals.⁹¹⁵

Careful digital extraction of meconium retained in the rectum may be all that is required in some foals. Manual retraction of manure with a self-contained basket (fecal loop) can easily traumatize the rectum. However, if used cautiously in the properly restrained foal, this technique may be successful in experienced hands. Analgesics may be required until the impaction passes. The prognosis in uncomplicated cases is good.



If the foal continues to strain after several enemas and colic signs persist, other diagnoses should be considered. Surgical intervention should be considered in foals that have progressive abdominal distention with poorly controlled pain. Surgical intervention in the foal less than 10 days of age is associated with a high mortality.⁹¹⁶ Adhesions were identified in 17% of the foals in one study that were recovered from general anesthesia but were subsequently euthanized because of recurrent colic.⁹¹⁵ Only 10% of foals less than 14 days of age survived, compared with 45.8% of foals 15 to 150 days of age.⁹¹⁶ Foals that fail to respond to initial therapy have a poorer prognosis that is associated with the treatment necessary to correct the condition.⁹¹⁷

Exploratory surgery is performed to correct the impaction and to rule out the presence of other mechanical obstructions or disease processes that mimic the clinical signs of meconium impaction. Sterile saline is infused through a large-bore needle positioned in the lumen of the small colon proximal to the impaction. The fluid is gently mixed with the impacted feces until the obstruction is broken down. If the impacted meconium cannot be removed with gentle massage or if the intestinal wall is compromised by the impaction, the impaction may be removed through a colotomy performed through the antimesenteric taenia of a healthy segment of colon. Small colon resection and anastomosis should be avoided if possible because this procedure complicates the postoperative recovery and is associated with a poor prognosis because excessive tension can develop at the surgical site, causing leakage.⁹¹⁸ Sepsis is a major cause of death after surgery in foals, even without obvious surgical complications.³⁰⁰

INGESTA IMPACTION

Clinical Signs

Small colon impactions usually affect horses in the fall and winter of the year. Horses more than 15 years old, ponies, and American miniature horses appear to be affected most often, and female horses are more commonly affected than males.^{919,920} Most horses have a noticeable reduction in fecal output and decreased borborygmi. Abdominal distention may be severe in horses with complete obstruction of the small colon, and heart rate, abdominal pain, and abdominal distention are pronounced in horses requiring surgery.

Diagnosis

Rectal examination is very helpful in the diagnosis of ingesta impactions of the small colon, in contrast to other causes of intraluminal obstruction (enteroliths, fecaliths, and fibrous foreign bodies), which tend to affect the proximal portion of the small colon. Clinicopathologic data are usually within normal limits.

Treatment

Horses that require surgical intervention tend to have abdominal distention, severe abdominal pain, and high heart rates. Surgical intervention should be considered when medical management fails, abdominal distention develops, or changes in peritoneal fluid indicate compromise of intestinal viability. Surgery should include a high enema, massage of the small colon to distribute the fluid within the impaction, and extraluminal manual evacuation of the contents. Although enemas may be successful in conscious horses in isolated instances, performance of this procedure with the horse under general anesthesia reduces the potential for perforation of the small colon.

Successful medical treatment requires early aggressive fluid therapy consisting of balanced polyionic fluids intravenously, laxatives (magnesium sulfate 110 g PO q12h) or lubricants (mineral oil 2 to 4 L) via nasogastric tube, and flunixin meglumine. Affected horses that can be treated medically have a good prognosis and reduced hospitalization time compared with horses that require surgical intervention. This was the case in a retrospective study of 28 affected horses in which early aggressive therapy was paramount to the success of medical treatment. All horses treated medically and 7 of 18 horses treated surgically were alive at least 1 year after discharge.⁹⁰⁸ Common complications after surgery included fever and diarrhea. Adhesions involving the small colon may develop, requiring a subsequent surgery or euthanasia.

FECALITHS, BEZOARS, ENTEROLITHS, OR FOREIGN BODY OBSTRUCTION

Fecaliths are composed of inspissated fibrous fecal material and are believed to form as a result of improper fecal ball formation, which is related to diet. Fecaliths tend to affect horses less than 1 year of age or more than 15 years of age, and males are more commonly affected than females.⁹¹⁹ Ponies, American miniature horses, mixed-breed horses, and Mustangs are more commonly affected than other breeds.⁹¹⁹ The condition is fairly common in ponies in the late fall, when grass becomes coarse and the cool weather causes a reduction in water intake.^{921,922}

Phytoconglobates are concretions of undigested food fragments and foreign particulate matter formed into balls. Bezoars are a combination of magnesium ammonium phosphate crystals with plant fibers (phytobezoars) or hair (trichobezoar) (Fig. 10-179). Phytobezoars are more common than trichobezoars or phytoconglobates. Bezoars have a smooth glistening surface, but are light-colored, unlike enteroliths which are usually dark.

Enteroliths are mineral concretions composed primarily of magnesium ammonium phosphate salts that are usually deposited concentrically around a foreign material



A



B




Fig. 10-179 A, This trichobezoar that obstructed the proximal small colon of a horse is composed of a combination of magnesium ammonium phosphate crystals with hair. Trichobezoars are less dense than enteroliths and have a velvety surface and a firm elastic consistency when indented by light finger pressure. B, Opening the trichobezoar reveals the hair mixed with other particulate and mineral fragments.

such as a stone or piece of metal (Fig. 10-180).^{755,756} The pitted, uneven surface of the obstructing mass, which is surrounded by firm concretions of digesta, lodges against the mucosa. The mass can reach 1 m (3.5 feet) in length and weigh as much as 7 kg (15.5 lb) or more.⁹²³ Enteroliths occur more commonly in horses 5 to 10 years of age, whereas foreign bodies cause obstruction in horses less than 3 years old. Enteroliths are generally more difficult to identify on transrectal palpation of the abdomen because they tend to lodge in the proximal portion of the small colon. Enteroliths have a tendency to develop more commonly in Arabian and female horses.⁹¹⁹ Foreign materials such as twine, rope, clothing, rubberized fencing materials, and tire threads are more commonly found in yearlings and weanlings.⁹²³



Fig. 10-180 These multiple small enteroliths were discovered during enterotomy of the large colon after removal of another enterolith that was lodged in the proximal small colon.

Clinical Signs

Horses with foreign body obstruction of the small colon are dull, anorexic, and have mild abdominal pain. They may exhibit tenesmus if the obstruction is near the rectum. Single or multiple loops of small colon with firm digesta can be felt on transrectal examination of the abdomen in approximately 30% of the cases.⁹²⁴ Some small enteroliths can pass in the feces, whereas larger enteroliths may transiently become lodged in the transverse colon and then return into the right dorsal colon.

With complete obstruction of the small colon, abdominal pain is persistent, tympany increases, and the patient's condition deteriorates. The intestinal wall surrounding the enteroliths may undergo pressure necrosis, and, if the condition is prolonged, the wall may perforate, leading to fatal peritonitis.

Treatment

These obstructions are best removed via a small colon enterotomy through a ventral midline celiotomy. Evacuation of the large colon should be performed if it contains a large volume of ingesta, because this will minimize stress on the enterotomy site after surgery.⁹²⁵ Enemas are not recommended for the correction of this condition.

With longer-standing obstructions caused by fecaliths, foreign bodies, or enteroliths, a local section of small colon wall may become devitalized by pressure necrosis. It may be possible to remove the damaged bowel wall by wedge resection, which is a simpler technique and less likely to result in complications than complete resection.



and anastomosis.⁹²² The prognosis associated with removal of these obstructions is good if the condition is recognized and corrected before the development of irreversible intestinal compromise.

ADHESIONS

Small colon adhesions commonly occur after colotomy of the small colon and may necessitate or complicate a subsequent surgery (Fig. 10-181). Adhesions can also develop after peritonitis because of inflammation, injury to the distal bowel after meconium impaction in foals, or rectal trauma in adults.

Treatment

As with most intraabdominal adhesions, treatment is difficult and unrewarding. Surgical intervention may resolve local adhesions that can be located and broken down, but these will often recur. The most effective treatment for adhesions is prevention by inhibiting or minimizing the inciting causes and aggressively treating conditions likely to result in peritonitis.^{926,927}

VOLVULUS

Volvulus of the small colon is rare. It may occur as a single event, may be associated with abnormalities and malpositioning of other organs, or may be a complicating factor of torsion of the gravid uterus in the mare.^{919,922}

Clinical Signs and Diagnosis

Pain is more severe than that associated with simple intraluminal obstruction because of the associated vascular compromise. The horse is less responsive to analgesics, and systemic signs of circulatory shock manifest rapidly. The heart and respiratory rates increase, abdominal distention develops, and abnormal findings are identified readily by transrectal palpation.⁹¹⁹ The peritoneal fluid has increased plasma protein concentration, and the number of WBCs, which are predominately neutrophils, is increased.

Treatment

The appropriate treatment is surgical correction of the volvulus and resection of devitalized bowel. Evacuation of the large and small colon and restriction of feed intake for several days are recommended to reduce the chance of postoperative small colon impaction.⁹²²

INCARCERATION

Causes of small colon incarceration include lipoma or ovarian strangulation, abdominal testicular teratoma, mesocolic rupture with segmental infarction, and granulosa cell tumors (Fig. 10-182).^{906,928-934} Rents or openings in the mesocolon are potential areas through which the small colon can become incarcerated.

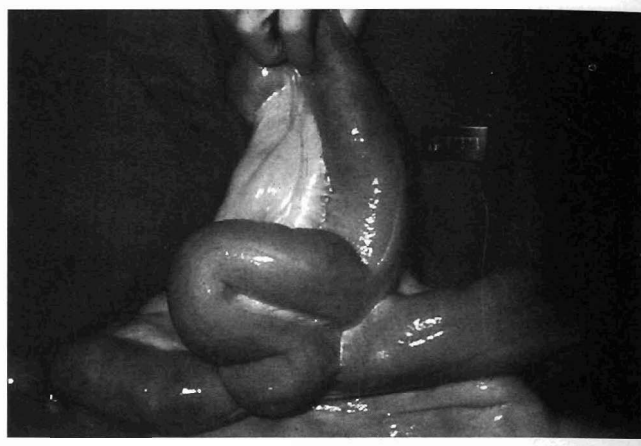

Fig. 10-181 Extensive adhesions of the small colon after a colotomy for removal of an enterolith 2 months earlier. These adhesions prevented the passage of fecal balls in the small colon, causing signs of obstruction colic.

Clinical Signs and Diagnosis

The clinical signs are usually more pronounced than those associated with conditions causing simple obstruction, and the protein concentration and WBC counts of peritoneal fluid increase rapidly. Segmental ischemic necrosis associated with discrete tears of the mesocolon should be considered in the differential diagnosis of colic in mares that have recently foaled, particularly when deterioration in the mare's condition is accompanied by increases in peritoneal fluid protein concentration, RBC percentage, WBC count, and palpable impaction of the descending colon.⁹²⁸

Treatment

Treatment for incarceration is via surgical exploration and correction. Resection and anastomosis are necessary because of severe compromise to the affected area (Fig. 10-182). The prognosis is directly related to the condition of the affected portions of bowel and necessity for resection. In one retrospective study of 102 horses that had surgery because of small colon disease, horses with vascular compromise of the small colon were more than 2 times likely to be euthanized at surgery. Short- and long-term survival rates of horses with strangulating obstructions are similar to those for horses with nonstrangulating obstructions of the small colon.⁹¹⁹

PEDUNCULATED LIPOMAS

Pedunculated lipomas originate as localized plaques of fat between two serosal layers of the mesentery (Fig. 10-183). As the aggregations of fat enlarge, the overlying serosa stretches, forming a pedicle, which lengthens as the weight of the lipoma increases. Contributing factors

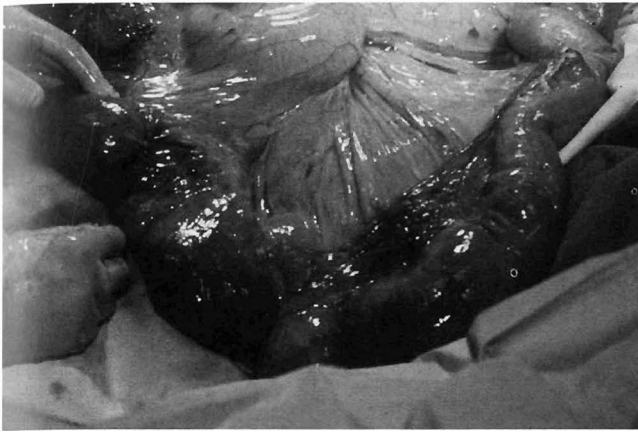


Fig. 10-182 Devitalized segment of the small colon resulting from incarceration by a mesenteric rent. Resection of the involved bowel and anastomosis of healthy small colon is necessary for survival.

to strangulation and obstruction of intestine by lipomas include the weight of the lipoma, the length of the pedicle, and body movements of the horse. Although lipomas more commonly involve the small intestine, lesions involving the small colon have been reported.⁹²⁹ Although it has been suggested that fat in the mesocolon and mesorectum predisposes these areas to the formation of lipomas, compared with the mesentery of the small intestine, the reports of strangulation of the small colon in this manner are rare. It also has been proposed that the short mesocolon and the fixed position of the small colon at the transverse colon proximally and the rectum distally make the small colon less likely to become strangulated compared with the relatively mobile small intestine.⁹²⁹

Clinical Signs and Diagnosis

Horses with lipomas incarcerating the small colon develop marked gas and fluid distention of the large colon with no evidence of small intestinal distention. Gastric reflux can be present if the proximal duodenum is compressed by the distended large colon. Palpation of the small colon incarceration and lipoma is not usually possible on transrectal examination because of the variable location of the lesion and mobility of the involved small colon.⁹²⁹

Treatment

Treatment of horses with strangulating lipomas involves resection of the lipoma at the base of its pedicle and resection of any compromised intestine. Evaluation of the serosal and mesentery color, reflex motility, pulse in the mesenteric vessels, and mucosal color via colotomy are indicators used to determine intestinal viability. The incidence of complications after resection and anastomo-

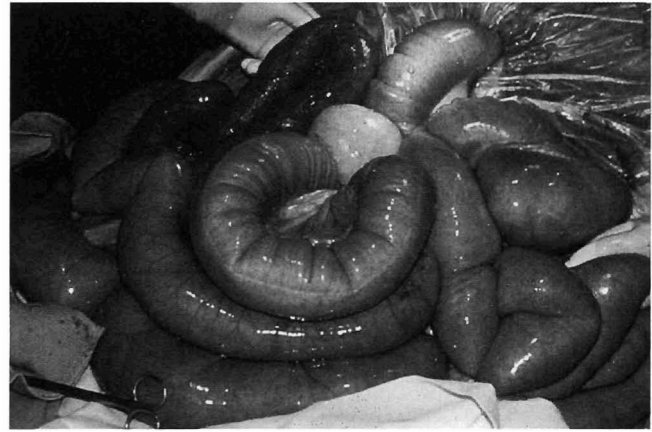


Fig. 10-183 Lipoma incarceration of the small colon. Normal and infarcted areas of small colon are present. Removal of the pedunculated lipoma and resection of the involved necrotic bowel was performed.

sis of the small colon are high because contamination is difficult to control with the inherent high intraluminal bacterial counts, solid ingesta that passes by the incision, and possible difficulty in adequately exposing the affected area. Collagenase activity in the descending colon, unlike most other tissues, is not restricted to the site of the trauma but is diffuse, thereby weakening the entire colon during the first few days after surgery. Bursting pressure studies of small colon after resection and anastomosis reveal that at 5 days after surgery the anastomosis site is as strong as the surrounding small colon.^{913,914}

If luminal diameters are maintained during intestinal anastomosis and there is little contamination by ingesta, abdominal drains need not be inserted nor are stainless steel sutures required for closure of the linea alba. Inflammation within the abdomen, as characterized by changes in peritoneal fluid constituents, is similar in magnitude after small colon resection and after routine manipulation of the abdomen for correction of displaced intestine.⁹¹⁴ Prognosis depends on the degree of endotoxemia associated with the intestinal compromise at the time of resection and the success of the anastomotic technique.

ABSCESSATION

Abscessation of the small colon or the mesocolon may develop as a sequela to rupture of a mesenteric lymph node associated with bastard strangles, focal postoperative peritonitis associated with an enterotomy, generalized septicemia, or trauma to the abdominal wall or rectum.

Clinical Signs and Diagnosis

Unless the lesion progresses to an extraluminal obstructive lesion, affected horses are usually intermittently

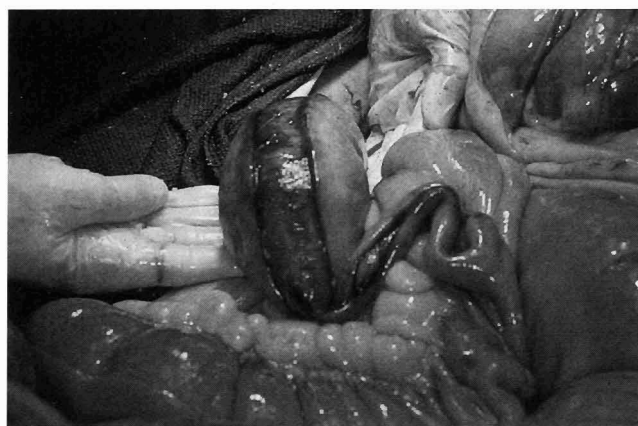

Fig. 10-184 Rupture of the serosal and muscular layers of the small colon along the antimesenteric taenial band resulting from obstruction by an intramural hematoma. The mucosa and submucosa are intact. The hematoma was removed and the tear sutured. Rupture along antimesenteric taenial band is a consistent finding in small colon rupture.

febrile and anorectic and lose weight. Although a specific diagnosis can usually be made only by exploratory celiotomy, a transrectal examination of the abdomen may be helpful.

Treatment

If the abscess is accessible, attempts can be made to break down the adhesions and drain or resect the abscess and diseased tissues. Marsupialization of the abscess for drainage is advisable for lesions that cannot be exteriorized. Prognosis is generally poor for correction of this condition because of the nature of the associated inflammation and peritonitis present.

INTRAMURAL LESIONS

Intramural lesions include intramural or subserosal hematomas, polyps, and leiomyomas. Equine myenteric ganglionitis, which causes signs of intestinal pseudoobstruction, is a mononuclear cell infiltration of the myenteric plexus that destroys normal gastrointestinal motility. Abdominal pain is usually mild initially but can progress if intestinal compromise or obstruction of the small colon develops. Submucosal and intramural hematomas may develop after parturition or ulceration of the mucosa or may occur as a result of rectal trauma and subsequent infection of the submucosa resulting in severe dissecting cellulitis with local hemorrhage.⁹³³ Horses with partial small colon obstruction usually respond to treatment with oral fluids and lubricants. In most cases this condition can be successfully treated medically with fecal softeners and dietary control. In more severe cases the hematoma can totally obstruct the lumen of the small

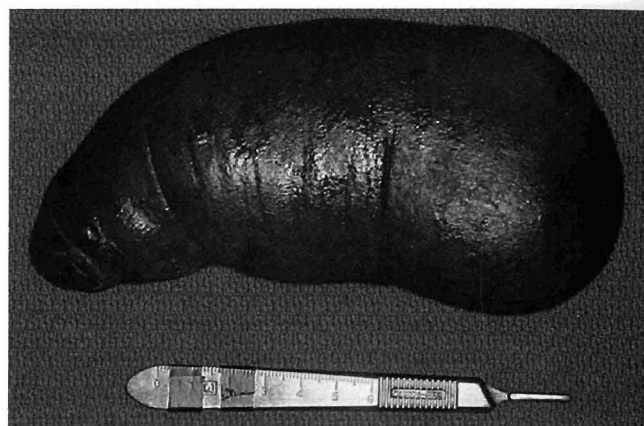


Fig. 10-185 An intraluminal hematoma causing obstruction of the small colon. Because the mass was detached from the lumen, it was successfully manipulated aborally out the rectum.

colon, causing the accumulation of feces and gas. As the distention of the bowel progresses, the abdominal pain becomes more severe, resembling that associated with a large colon displacement or volvulus. Rupture of the small colon with soilage of the abdomen can occur rapidly (Fig. 10-184). Surgical intervention is necessary to resect the affected portion of the devitalized small colon.^{931,933} The prognosis is good for recovery if the affected bowel can be successfully removed before endotoxemia develops and if lumen diameters are maintained.^{931,933} When the small colon is not devitalized and the hematoma is detached from the lumen, it can be manipulated aborally out the rectum without the need for a colotomy or resection (Fig. 10-185).

Leiomyomas are tumors of smooth muscle that rarely occur in the horse. The tumor is usually associated with the small intestine; however, it has also been identified in the small colon and rectum.⁹³⁵ Leiomyomas are invasive locally, suggesting that early surgical treatment may be curative. Clinical signs are usually associated with a history of recurrent abdominal pain that progresses in nature as the degree of obstruction increases. These lesions require resection and anastomosis.⁹³⁵ Prognosis depends on corresponding vascular lesions and the success of the resection and anastomosis in creating adequate lumen diameters without excessive contamination of the abdomen. Emptying the large colon during surgery, along with the administration of intestinal lubricants, intravenous fluids, and analgesics postoperatively lessens the incidence of anastomotic leakage and dehiscence.

INTUSSUSCEPTION

Intussusception rarely involves the small colon of the horse. Most reported cases involve protrusion of a



portion of the small colon and rectum from the anus and are classified as type IV rectal prolapses.^{932,936}

Clinical Signs and Diagnosis

The clinical signs consistent with small colon intussusception are chronic intermittent abdominal pain with anorexia and lethargy. Affected horses may develop an acute episode of continuous severe abdominal pain if the obstruction becomes complete. The abdomen is distended, and transrectal examination reveals moderate distention of the large colon and cecum, with a tense, painful viscus in the ventral abdomen just rostral to the pelvic brim. Abdominal paracentesis reveals an increase in the nucle-

ated cell count and protein concentration, and mild-to-moderate degeneration of neutrophils.

Treatment

Resection of the diseased bowel with anastomosis of the normal small colon relieves the intraluminal obstruction and source of toxemia.⁹³⁶ The prognosis depends on the extent of the preexisting toxemia and success of intestinal resection and anastomosis in portions of the small colon that can be exteriorized. Early and proper treatment of parasites and diarrhea to limit small colon inflammation and straining may help prevent this condition.⁹²⁷

Diseases of the Rectum

R. REID HANSON

Diagnostic and Therapeutic Considerations

The rectum extends from the pelvic inlet to the anus and is approximately 30 cm (12 inches) long in an adult horse.³⁹⁷ The rectal peritoneal reflection is attached dorsally and is a continuation of the mesocolon. The rectal ampulla is a dilation of the retroperitoneal part of the rectum that is formed by thick longitudinal muscle bundles. The anal canal is approximately 5 cm (2 inches) long and is enclosed by the internal anal sphincter, which is a thickening of the circular smooth muscle and the external anal sphincter. The latter is composed of striated muscle.³⁹⁷ The levator ani muscle originates from the ischiatic spine and sacrotuberale ligament and inserts at the external anal sphincter. This muscle restricts the tendency of the anus to prolapse during defecation.³⁹⁷

Dietary modification is generally necessary for horses undergoing surgical correction of rectal tears, prolapses, or diverticula or pararectal abscesses.⁹³⁷ Fecal consistency is altered by laxative diets (alfalfa hay, lush pasture grass, and bran mashes) or the administration of mineral oil, DSS, magnesium sulfate, or psyllium. All have been used as laxatives with varying degrees of success. A low-fiber, low-residue diet is a valuable adjunct to the management of rectal tears, prolapses, perineal lacerations, or rectovaginal fistulae, because these conditions require radical and tenuous reconstructive procedures that are susceptible to incisional dehiscence secondary to tenesmus or rectal impaction.⁹³⁷ Pelleted diets in combination with a reduction of the roughage portion of the diet and the administration of magnesium sulfate 0.5 kg q12h by nasogastric tube has been an effective, consistent way to soften the feces. Enteral diets that are low in residue may

be useful in the medical or postoperative surgical management of horses in which low fecal residue and loose fecal consistency are desirable. These diets may prove to be useful in the postoperative nutritional management of rectal surgery patients.

When performing any procedure in the perineal region, the surgeon is at increased risk of serious injury should the horse kick. Therefore careful physical examination associated with assessment of the anticipated responses to surgical manipulation of the perineal region are strongly advised. Horses should be restrained in stocks that permit safe and effective confinement while allowing unrestricted access to the surgery field. Because administration of a caudal epidural anesthetic is appropriate for many perineal surgeries, regional anesthesia should be administered before routine aseptic preparation and draping of the operative field. The cranial rectum should be evacuated manually and packed with rolled cotton to prevent intraoperative contamination of the surgical site with fecal material. The tail should be wrapped and secured to the horse's neck with a tail tie. To ensure a safe working environment for the animal and operator, the patient should be sedated or tranquilized.

Congenital and Familial Diseases

ATRESIA COLI

Atresia coli, which is more appropriately classified as an absence of myenteric ganglia in the terminal portion of the ileum, cecum, and entire large colon is a rare disorder in foals that has been reported in association with the recessive lethal white gene.³⁰⁸ This condition is more commonly known as *lethal white syndrome*. Two types of

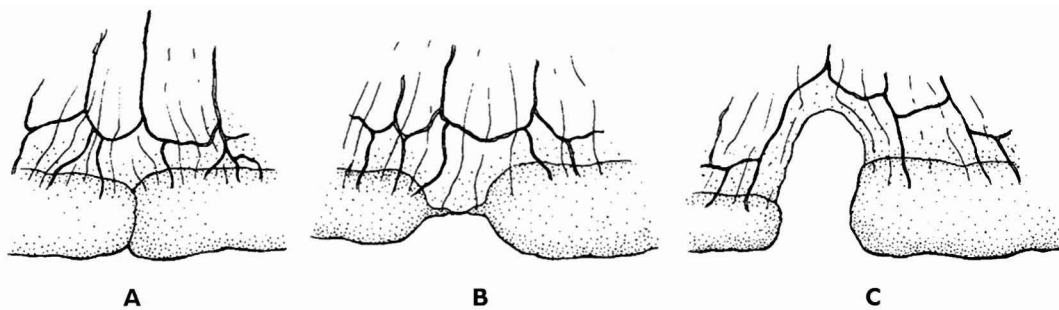


Fig. 10-186 Atresia coli can also be caused by a congenital lack of blood supply that is not related to the overo white syndrome. These foals have a blind end atresia caused by an absence of a segment of the large, transverse, or small colon with disconnecting blind ends or a gap in the mesentery. These closures can manifest themselves as **A**, diaphragm closure, **B**, blind ligamentous closure, or **C**, complete separation of the bowel wall.

(Redrawn from Schneider JE: *Proc 27th Annu Mtg AAEP*, 1982, p 287.)

lethal white syndromes have been reported in the foal.⁹³⁸ One is a dominant gene that causes early embryonic death in the homozygous condition.^{307,308,924,939} The other is a recessive gene that results from the breeding of two overo paints.^{307,308,924,939} In the recessive condition it is theorized that there are two alleles for recessive white spotting in the horse homologous to *s* and *s'* coloring in other mammalian genetics. When the *s'* becomes homozygous the overo white foal syndrome is the result.⁹⁴⁰ The most significant finding at necropsy is a denervated, narrow but pale segment of the terminal large colon. Denervated smooth muscle is usually sensitive to stimuli and tends to remain permanently contracted.³⁰⁸ Although the terminal large colon is anatomically patent, the end result of the aganglionosis is a physiologic stenosis. This is due to the fact that the alleles at the *s* locus affect the migration of cells from the neural crest during the embryonic development. Neural crest cells form melanocytes responsible for pigmentation and also migrate to form the ganglion cells of the myenteric plexus. The absence of these ganglion cells of the colon seems to retard the development of the colon. Histologic examination shows a correlation between the number of ganglion cells and the severity of stenosis of the colon. The fewer ganglion cells present the more severe the stenosis.

Atresia coli, however, has also been reported in other foals lacking this gene.^{941,942} These foals have a blind-end atresia caused by an absence of a segment of the large, transverse, or small colon, with disconnected blind ends and a gap in the mesentery (Fig. 10-186). The atresia is thought to be caused by a congenital loss of blood supply (Fig. 10-187). Atresia coli has also been reported in one foal with a concurrent presumptive diagnosis of equine rhinopneumonitis;

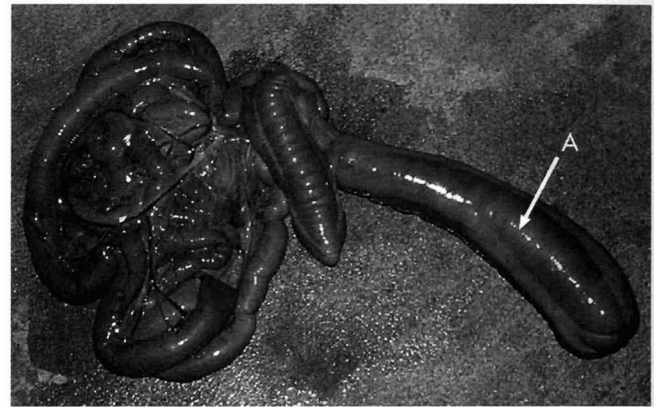


Fig. 10-187 Blind end atresia in a neonatal foal with absence of the right dorsal, transverse, and small colon, resulting in a complete obstruction of the bowel. The large colon (**A**) was one large blind-ended pouch without distinction of a separate ventral and dorsal chamber.

however, no specific relationship was found between the two.⁹³⁹

Clinical Signs

Lethal white foals, which have pink skin and pale mucous membranes, appear normal at birth; however, they fail to pass meconium and quickly develop colic. Digital rectal examination fails to detect feces. When the colon and rectum are complete, a bulge in the anal membrane may be present as a result of increased abdominal pressure. Because of the intractable pain and poor prognosis, most foals are euthanized within 24 hours of birth.

Atresia ani is confirmed visually. Palpation of meconium through the dorsal vaginal wall in females and over the anus in male foals is usually diagnostic of a complete



rectum. In contrast, foals with atresia ani begin to show signs of abdominal pain shortly after birth, as they strain to defecate and flag their tails repeatedly.

Diagnosis

Atresia coli or recti can be confirmed radiographically by the administration of a barium enema, endoscopy, or exploratory surgery. Stenosis of the colon, rectal atresia, and a paucity of ganglia in the ileum, colon, or transverse colon have been reported in these foals.^{307,308}

Other congenital abnormalities of the intestinal tract are rare and can occur at any level.³⁰⁸ Atresia coli and ani may occur alone or may be associated with atresia recti, persistent cloaca, absence of a kidney, renal hypoplasia and dysphasia, absence of the tail, musculoskeletal deformities, microphthalmia, rectourethral fistula, and other uroperitoneal anomalies.^{938-940,943-948}

Treatment

In foals with atresia ani and a complete rectal pouch, the persistent anal membrane is incised or a small circular piece of skin is removed while the anal sphincter is spared. The rectal wall is then sutured to the skin with simple interrupted sutures. If the distal portion of the rectum is atretic, deeper dissection may be required to locate and mobilize its blind end for suturing to the skin. If the entire rectum is atretic, exploratory surgery would allow evaluation, and, if feasible, correction of the condition. Most of the lesions, however, are inoperable, and attempts to reconstruct the atretic colon have a high failure rate.

In foals with atresia ani a careful examination should be performed for the presence of other congenital lesions. In one report of 608 deformed foals, 19 had intestinal lesions with atresia of the anus being the most common lesion. Other lesions are also commonly associated with atresia ani, such as acaudia, cleft palate, renal hypoplasia, hypoplasia of the coccygeal vertebrae, persistent cloacae, and rectovaginal or rectourethral fistulae. Atresia ani without associated urogenital anomalies is reported to occur in dogs, cattle, buffalo, sheep, goats, pigs, and horses.^{943,944,946,947,949} Although there are no data to confirm a hereditary basis for the disorder in horses, it would be unwise to repeat a mating that resulted in a confirmed case.

Further examination using urethral catheters, endoscopy, and contrast radiography will assist in the diagnosis of rectourethral or rectal vaginal fistulae. These conditions can be corrected surgically with staged repair of the defects using a rectal pull through after excision of the stenosed anus, closure of the anobulbar fistulae, and restoration of the perineum.⁹⁴³ Bowel incontinence is not a problem in an equine patient that lacks sphincter control. Provided that they have no other congenital

deformities of the bowel, these animals can mature as serviceable animals.

Diseases with Physical Causes

RECTAL TEAR

Although rectal tears are most commonly encountered in Quarter Horses and Arabians, they can occur in any breed. In one retrospective study, the condition occurred in females 77% of the time and usually during evaluation of the urogenital tract. Twenty-seven percent of the lesions were incurred while evaluating the gastrointestinal tract.⁹⁵⁰ Horses with thromboembolic disorders may be at risk for rectal perforations resulting from ischemic necrosis caused by thrombosis of the caudal mesenteric artery and its branches.⁹⁵¹ Other less frequent causes of rectal tears include breeding accidents and dystocia.⁹³⁷

Clinical Signs

Most rectal tears occur in association with rectal palpation and should be suspected when a sudden decrease in the resistance to palpation is felt or when fresh blood is observed on the palpation sleeve.^{937,950} With grade 3 or 4 tears the horse will begin to sweat, develop an increased heart rate, fever, abdominal pain, and splinted abdomen in 2 to 3 hours consistent with signs characteristic of septicemia, endotoxic shock, and peritonitis.⁹⁵² Most rectal tears occur dorsally, in a longitudinal direction 25 to 30 cm (10 to 12 inches) cranial to the anus in the intraperitoneal portion of the rectum and dissect obliquely for a variable distance along the lateral wall.^{950,953} In this region there is a decrease in the circular muscle thickness that corresponds with the increase in thickness of the mesenteric taenial band of the small colon. The decrease in circular muscle thickness and a lack of serosal surface of the bowel enclosed in the mesorectum could contribute to the inherent weakness at this site. Rectal tears that occur caudal to the peritoneal reflection may lead to a retroperitoneal abscess that could extend into the abdominal cavity or require draining into the rectum, vagina, or perineum.⁹⁵⁴

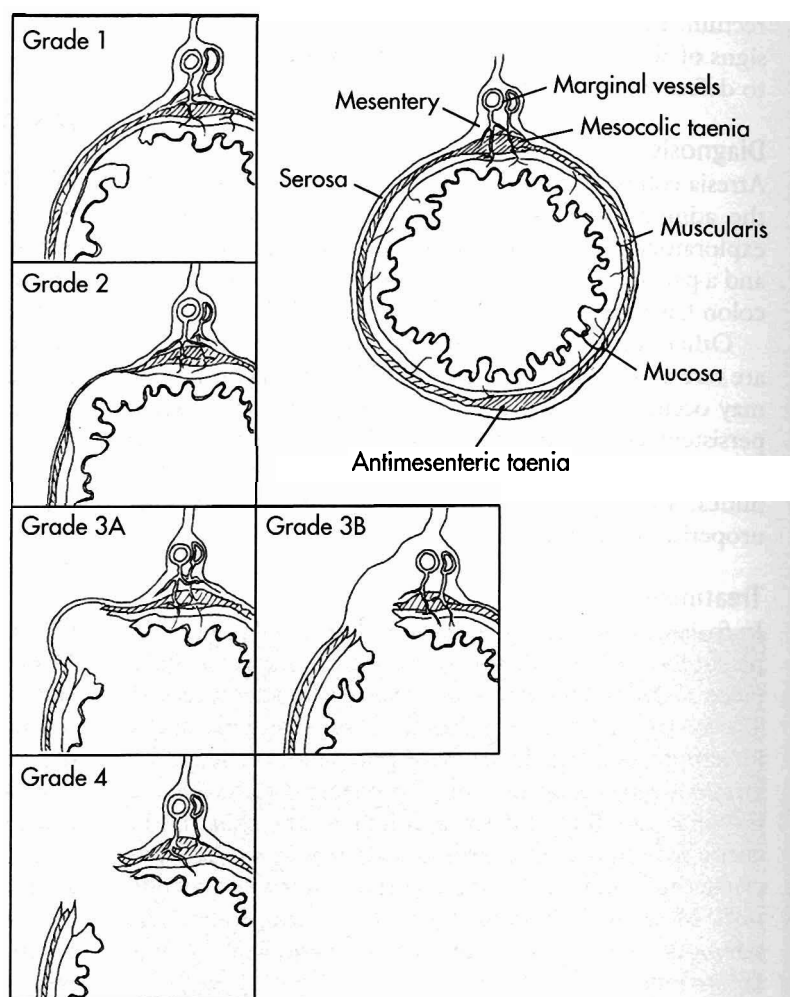
Diagnosis

Rectal tears have been classified on a four-grade system (Fig. 10-188). Grade 1 tears are restricted to the mucosa and submucosa and palpate as small roughenings or defects in the rectal wall associated with bleeding. Grade 2 tears involve only the muscular layers of the rectal wall, and the mucosa and serosa remain intact. No blood is seen on the rectal sleeve, and these are considered to be incidental findings.⁹³⁷ Grade 3 lesions involve all tissue layers except the serosa or mesorectum. There are deep defects that are often filled with feces. Grade 3A tears



Fig. 10-188 A grade 1 defect is palpated as a slight decrease in rectal wall thickness. The muscle fibers rather than the intact mucosa are palpable, but the cylindrical nature of the bowel is preserved. In grade 2 tears the mucosa remains intact but there is a defect in the muscular layer that gives the bowel wall its cylindrical shape. These tears are usually incidental findings, because luminal bleeding is not associated with these tears. Grade 3 rectal tears disrupt the mucosa, submucosa, and muscularis. Grade 3A tears usually form a diverticulum lined by serosa, which fills with feces shortly after the injury. Grade 3B tears allow fecal contamination of the mesocolon. Fecal contamination of grade 3 tears may cause progression to a grade 4 tear. Grade 4 tears are easily detected with direct palpation of abdominal organs.

(Redrawn from Rick MC: *Vet Clin North Am Eq Pract* 5:410-413, 1989.)



have the serosal covering of the bowel intact, whereas grade 3B tears occur dorsally into the fat-filled mesorectum. Grade 4 tears involve a perforation of all layers of the rectal wall, which permits direct communication between bowel contents and the abdominal cavity. Palpation of the abdominal organs directly is possible through a grade 4 tear. Circumferential retroperitoneal rectal tears have been reported but are infrequent.⁹⁵⁵

When a rectal tear occurs, prompt action will often improve the patient's chance of survival and the veterinarian's defense against litigation. An epidural anesthetic and sedation (xylazine 0.4 mg/kg IV and butorphanol tartrate 0.05 mg/kg IV) will help facilitate a careful examination of the rectum. Careful determination of the extent and exact location of the tear can be facilitated by bare arm palpation or cutting the fingers off a normal rectal sleeve and using a latex examination glove over the exposed fingers.^{954,955a} The feces should be carefully removed from the rectum before beginning the rectal examination. The tear may then be located by sequen-

tially inserting a hand into the rectum further each time, until blood is observed. A vaginal speculum can help to visualize the tear; however, the rectal mucosa usually folds around the speculum, making direct visualization difficult. Careful palpation will determine the severity of the tear once it is located. The tear should be very gently felt for position, distance from the anal sphincter, size, and depth. Any feces in or around the tear should be very carefully removed. The improper healing of grade 1 or 2 rectal tears can lead to abscess and or fistula formation.⁹⁵⁶ Grade 2 tears may be felt on subsequent rectal palpations as a variable-size diverticulum that is more accurately described as a mucosal-submucosal hernia.^{955a} These tears are usually incidental findings, because luminal bleeding is not associated with these tears. Grade 3A tears usually form a diverticulum lined by serosa, which fills with feces shortly after the injury. Grade 3B tears allow fecal contamination of the mesocolon. Fecal contamination of grade 3 tears may cause progression to a grade 4 tear. Grade 4 tears are easily detected with direct

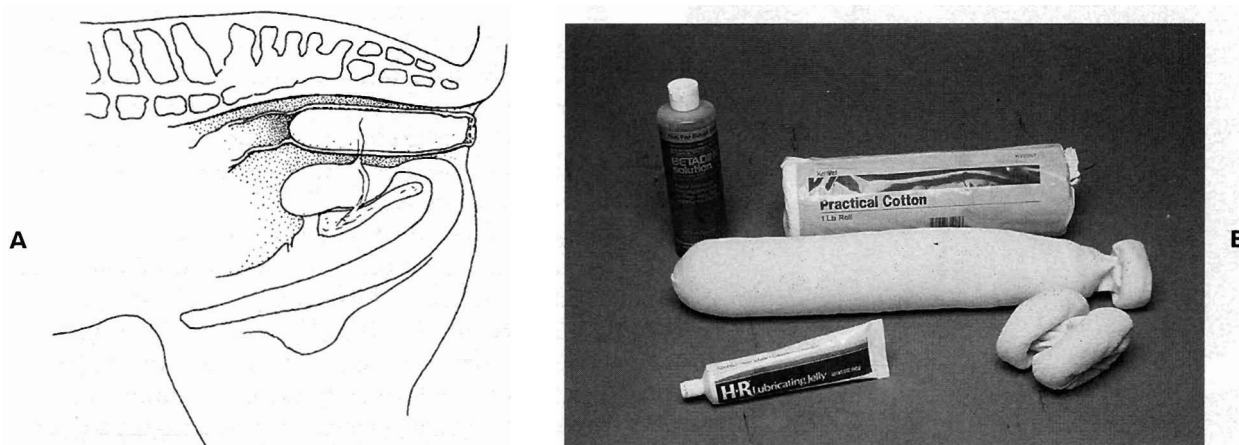


Fig. 10-189 A, A cotton-filled stockinette is used in association with epidural anesthesia to pack the rectum to prevent the gross fecal contamination or progression of the rectal tear. A purse-string suture is applied to the anus to secure the rectal packing before definitive correction. B, Items used to make the rectal packing include moist cotton placed inside a 3-inch stockinette. A copious amount of Betadine solution and lubricating jelly is applied to the surface of the rectal packing before insertion. Epidural analgesia alone will not prevent gross fecal contamination of grade 3 tears. Epidural analgesia combined with proper, immediate rectal packing is a safe, effective way of preventing gross fecal contamination of a grade 3 rectal tear between the time of injury and definitive treatment.

palpation of abdominal organs.⁹⁵⁷ Peritoneal fluid changes occur quickly in horses with grade 3 and 4 rectal tears, with nucleated cell counts exceeding 50,000 cells/ μ L in 30 minutes.^{955a}

Treatment

Accurate and early treatment has a marked influence on case survival. Horses with grade 1 tears are amenable to medical treatment alone or can be treated using epidural anesthesia with direct suturing techniques in the standing animal.^{955a} Broad-spectrum antibiotics should be administered with serial hemograms and peritoneal fluid analyses to aid in monitoring the patient. The horse should be monitored closely for 1 week and fed a laxative diet, such as water-soaked alfalfa pellets, combined with regular administration of mineral oil by nasogastric tube. Oral or intravenous fluid replacement may be required to restore circulating volume, ensure tissue perfusion, and prevent bowel stasis and possible colon impaction.

Grade 2 tears are discovered as an incidental finding on subsequent rectal palpations. Horses with grade 2 tears may present with signs of tenesmus or with rectal impactions. The hernia or diverticulum is usually detected after manual evaluation of the rectum. These tears occasionally lead to the formation of a perirectal abscess. Grade 2 tears are frequently manageable with conservative measures such as dietary control aimed at keeping the feces soft.^{955a}

Horses with grade 3 rectal tears require prompt and aggressive medical and surgical intervention. Early recog-

nition of the condition, along with aggressive precautionary measures to arrest the further development of the tear are indicated. Surgical intervention should be instituted immediately, for delaying repair only increases the mortality rate associated with the disease.

The immediate goal is to prevent enlargement and development of a grade 4 tear.⁹⁵⁷ This is accomplished by tranquilizing the horse, providing epidural anesthesia to eliminate straining, manually removing feces from the rectum, and packing the rectum to prevent fecal contamination and diverticulum formation.^{957,958} Epidural anesthesia should be maintained to prevent the horse from straining against the pack.⁹⁵⁷ A combination of xylazine and mepivacaine may be useful to provide a long-acting effect.^{959,960} All feces within reach are removed from the rectum and small colon, and the rectum is packed with moist cotton inside a well lubricated 7.6-cm (3 inch) stockinette (Fig. 10-189). The purpose of the packing is to fill, but not distend, the rectum. The pack should extend from the anus to approximately 10 cm (4 inches) cranial to the site of the tear.^{954,957,958} No material should be packed into the tear itself. The anus is then closed with towel clamps or a purse-string suture to prevent the packing from exiting (Fig. 10-190). Vigorous medical management should be instituted. Atropine, a parasympatholytic drug, has been recommended by some clinicians to depress intestinal motility.^{955a} When used correctly as a single dose (0.044 mg/kg IM or SC [20 mg for a 450-kg {90 lb} horse]), atropine will

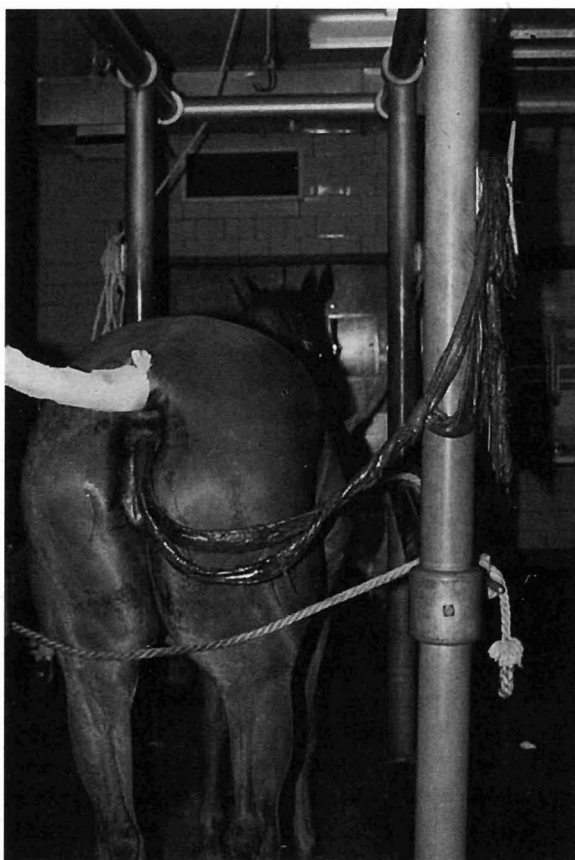


Fig. 10-190 Evisceration of the small intestine through a grade 4 rectal tear. The horse initially had a grade 3 tear. Epidural anesthesia and rectal packing were not initiated after the tear developed. It subsequently developed into a grade 4 tear during transport to a referral hospital.

decrease intestinal motility for up to 12 hours. This can be a safe and excellent way to depress intestinal motility. Broad-spectrum systemic antimicrobials, tetanus toxoid, and fecal laxatives such as mineral oil should also be administered. Balanced polyionic fluids should be administered to rehydrate the horse in anticipation of an extensive surgical procedure and to counter the hemodynamic effects of endotoxins.

Several surgical techniques have been described to repair rectal tears. These include direct surgical repair via a rectal approach, partial prolapse of the rectum, placement of a temporary diverting colostomy, placement of a temporary rectal liner, and direct surgical approach and repair via a celiotomy.* The technique chosen to repair the rectal injury depends largely on the location of the tear, the preference and expertise of the surgeon, and the availability of specialized surgical equipment.^{955a}

Techniques used to repair grade 3 tears also apply for

grade 4 tears. Because there is more direct contamination of the abdomen in grade 4 tears, there is an increased expense resulting from the likelihood of multiple post-operative complications. As a result, a poorer prognosis is associated with grade 4 tears; therefore the value of the animal in perspective to the expenses incurred should be taken into consideration.^{963,964}

Direct closure of grade 3 tears can be done in the standing animal if the tear is less than 15 cm (6 inches) from the anus.^{950,964} The horse must be cooperative and have a rectum that is easily dilated. The surgeon must have the patience and manual dexterity to close the wound without further damaging the edges of the tear or incorporating nearby mucosal folds into the tear, thereby reducing the rectal diameter.

An interrupted cruciate pattern using size 0 or 1 absorbable suture material, with a swaged-on, taper point, half-circle needle incorporating all layers is the method of choice.⁹⁶⁴ The tear can be repaired blindly with the sewing hand inserted into the rectum.⁹⁵⁰ Incomplete suturing of the tear, however, will allow for continual packing of the defect with feces and eventual breakdown or submucosal dissection. The use of an expandable rectal speculum or wire basket and long-handled instruments can facilitate closure of these tears for individuals inexperienced with the blind suturing method. Transection of the anus will improve access to the tear and facilitate defecation after surgery.⁹⁵⁵ Contraction of the wide muscular bands and circular smooth muscle increases the risk of dehiscence of the sutured tears. With proper patient selection (grade 3A tears), primary closure of the tear with sutures has yielded excellent results in six of seven patients.⁹⁵⁰

Direct suturing of the tear can also be achieved by prolapsing the small colon until the tear is exposed outside the anus. A hand is passed through the rectum to grasp the colon wall around a gauze sponge placed by an assistant through a laparotomy.⁹⁴⁵ Surgical stapling equipment has been successfully used to repair rectal tears exteriorized via suture traction of the rectum and wound edges.⁹⁶⁵ This procedure is more easily accomplished in thin horses, because less pressure is applied on the mesenteric vessels during traction of the small colon.

Placement of a temporary rectal liner via a ventral midline celiotomy has been described for the treatment of grade 3 or 4 tears.⁹⁶⁶ Each end of a 5- × 10-cm (2 × 4 inch) plastic rectal ring is trimmed to form a 5- × 7-cm (2 × 2.75 inch) ring (Fig. 10-191). Holes are drilled 1.5 cm (0.5 inch) apart in one edge of the central groove around the circumference of the ring, and no. 5 Dacron suture material is laced through the holes, forming a continuous anchor suture. The rectal ring is inserted into the small end of an arthroscopy camera sleeve. Modern rectal palpation sleeves have proven unreliable,

*References 927, 945, 951, 953, 954, 961 to 969.

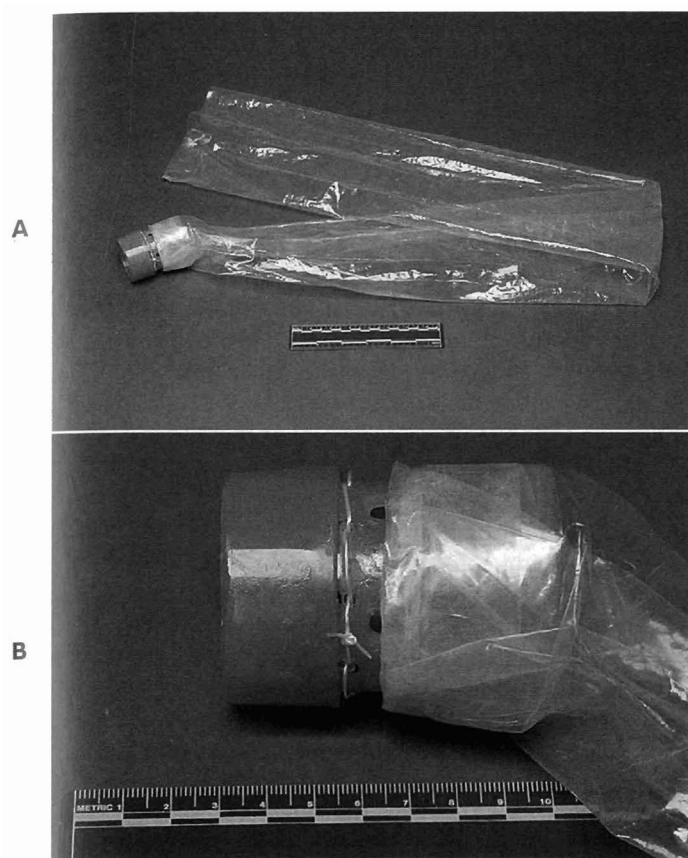


Fig. 10-191 A, A temporary indwelling rectal liner can be secured oral to the rectal tear for the diversion of feces past the tear. B, An assistant passes the plastic ring and sleeve through the anus and oral to the tear, where it is surgically placed. Feces that enter the ring are contained within the liner until passed through the anus. The temporary indwelling rectal liner maintains continuity of the rectum until the ring and circumferential suture slough 9 to 12 days after surgery. The temporary indwelling liner effectively protects grade 3 tears during healing, unless the tear converts to a grade 4 tear.

creating the need to use the more durable camera sleeve. A rubber band is placed around the sleeve and over the center groove in the ring at the opposite end from the anchor suture. The sleeve is fastened to the end of the ring with cyanoacrylic, and the sleeve is inverted over the ring and fastened to itself. Inversion of the sleeve protects the intestine against irritation by the rubber band, the cut edges of the sleeve, and the cyanoacrylic.⁹⁶⁶ An assistant passes the plastic rectal ring and sleeve through the anus and small colon until it can be surgically placed oral to the tear. No. 3 surgical catgut is passed around the colon and over the groove on the ring and is tied to constrict the serosal surface. Four interrupted retention sutures are placed equidistant through the colon wall to include the circumferential catgut suture and the Dacron suture in the rectal ring.

Absorbable retention sutures (2-0 in a Lembert pattern) are then oversewn over all previous sutures so as to infold the wall.

The large colon is evacuated by a pelvic flexure enterotomy, and a stomach tube is passed retrograde from the anus up the sleeve to thoroughly flush the small colon with water and infuse 4 L of mineral oil into the right dorsal colon.^{913,966} Feces that enter the ring are contained within the liner until passed through the anus. The anastomosis maintains continuity of the intestinal tract until the ring and circumferential suture slough 9 to 12 days after surgery. The temporary indwelling liner effectively protects grade 3 tears during healing, unless the tear converts to a grade 4 tear. The horse is kept standing until the rectal tear heals, because the sleeve could retract into the rectum if the horse becomes recumbent. Mineral oil and a pelleted ration are fed until the ring and liner detach.⁹⁶⁶

Thirty-five horses with grade 3 or 4 rectal tears were evaluated in one retrospective study and subclassified according to whether the remaining tissue in the tear was serosa (grade 3A) or mesorectum (grade 3B). Five horses were destroyed on presentation, and 30 were treated by primary suture closure (8 horses), fecal diversion alone (9 horses) or in combination with suture closure (11 horses), and packing of the tear with medicated gauze sponges (2 horses). Fecal diversion was achieved with a temporary indwelling rectal liner in 19 horses and colostomy in one. Survival was related to classification of the tear, efficacy of urgent care measures administered at time of injury, and method of treatment. Seventy-four percent of horses with grade 3A tears and 44% of those with grade 3B tears survived. Horses with grade 4 tears had a grave prognosis. Horses given adequate urgent care before admission had a better survival rate.⁹⁶⁶ With proper patient selection, primary closure of the tear with sutures yielded excellent results. In horses that were not candidates for suture closure alone, a combination of fecal diversion and suturing gave better results than fecal diversion only. In addition, selected horses were treated successfully by packing the rectal tear with gauze sponges.

Tears into the dorsal mesentery are difficult to repair via laparotomy, because the dorsal position limits surgical exposure and the edges of the tear are difficult to identify. The location of most tears, dorsally in the mesocolon or mesorectum and so far caudally, often makes exposure poor and very seriously limits visualization. If the tear is inaccessible because of its dorsal position but far enough cranial to approach via a ventral midline celiotomy positioned close to the brim of the pelvis, a direct suture repair via colotomy on the antimesenteric side of the small colon may be possible.⁹⁶⁷ Evaluation of the contents; traction and, possibly, elevation of the horse's



hindquarters; or caudal retraction of the rectum may be necessary to allow access to the tear.⁹⁶⁷ A caudal-to-ventral midline celiotomy, small colon colotomy, and evacuation of feces from the large colon is a lengthy procedure. Two surgical teams could perform these procedures simultaneously to minimize operating time, although accessibility to the tear would be the key factor. If closure of the tear is not possible, options include procedures such as placement of a temporary rectal liner or colostomy.

Diverting colostomies require one surgical procedure to create the colostomy and an additional surgery to resect the colostomy and restore the continuity of the small colon after the rectal tear has healed.⁹⁵³ A diverting colostomy may be performed as a loop or end-on colostomy, depending on whether an intact loop or a transected segment of small colon is sutured to a body wall incision.^{945,953,955a,970} Direct suturing of grade 3 tears, if possible, is recommended to reduce the size of the tear and prevent the tear from converting to a grade 4 tear. Failure to close the tear could likely result in a

complete "ostomy" forming at the site of the original tear between the intestinal mucosa and peritoneal cavity, with subsequent fatal peritonitis after the ring and liner are passed.^{964,966}

Diverting colostomies can be performed with the horse standing, using sedation and local anesthesia, or with the horse under general anesthesia. Advantages of the standing procedure include the elimination of risk of damage to the stoma during recovery from anesthesia, less expense, and elimination of possible complications incurred during general anesthesia. Advantages of performing the colostomy with the horse under general anesthesia include the greater ease of tissue handling with the horse in lateral or dorsal recumbency. In the presence of peritoneal inflammation, the unanesthetized horse may be reluctant and unwilling to permit any traction and manipulation of the bowel.^{955a}

The diverting colostomy can be performed through a single 12-cm (4.75 inch) vertical incision in the lower flank region, midway between the level of the tuber coxae and the level of the coxofemoral joint (Fig. 10-192). The

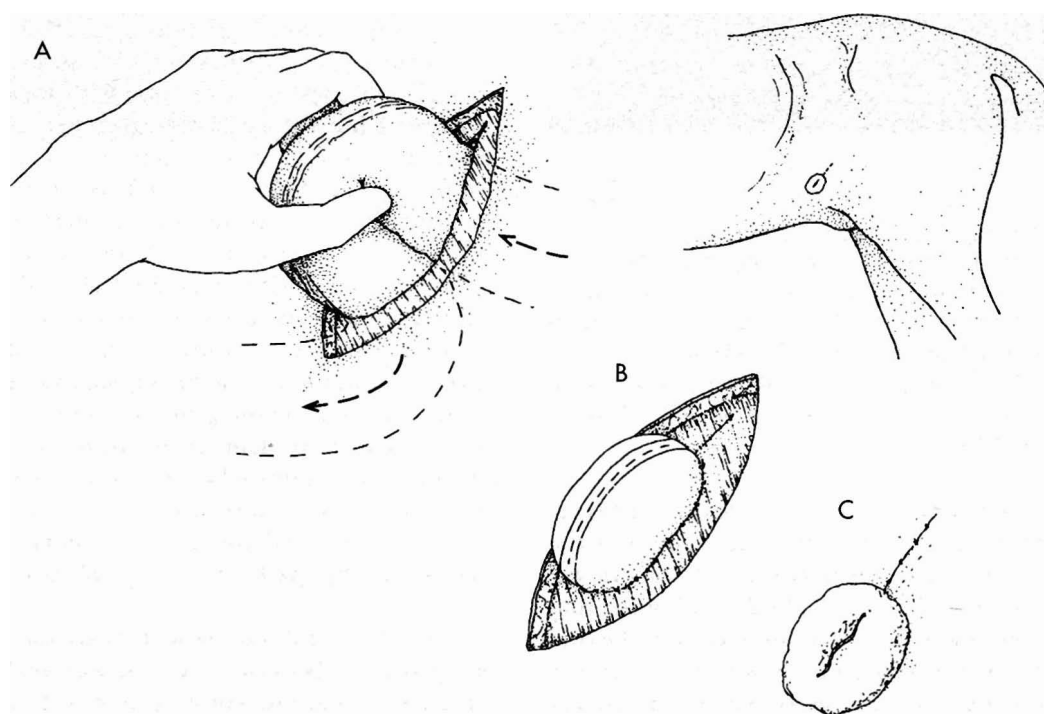


Fig. 10-192 Loop colostomy procedure. **A**, The small colon is pulled through the lower body wall, and, **B**, the serosal surface of the small colon is attached to the external abdominal oblique muscle. **C**, The seromuscular edges are sutured to the subcutaneous fascia, and the mucosal edges are sutured to skin in a simple-interrupted fashion. The proximal edge of the stoma should open slightly cranial and ventral to the distal segment and the lumen diameter should be preserved. If surgery is performed with the horse under general anesthesia, the above-mentioned procedure can be used or a single flank incision can be made in the ventral abdomen to accommodate the sutured-loop stoma. For the latter approach, the body wall incision is closed until it forms a snug fit around the colon in its ventral commissure. The loop colostomy is easier to perform than the end-on colostomy and allows for the continual lavage of the distal rectum.



subcutaneous tissues and external abdominal oblique musculature are transected sharply, and the transverse abdominal muscles are dissected bluntly parallel to their muscle fibers. A loop of small colon approximately in the middle of its accessible length is exteriorized. The loop is oriented with the proximal end of the colonic loop at the cranioventral aspect of the incision.⁶⁷⁶ A loop of intestine with the antimesenteric surface pointed outward, approximately 8 cm (3 inches) long, is sutured to the edges of the external abdominal oblique muscle and fascia with size 0 absorbable suture in a simple-interrupted pattern. A 6-cm (2.5 inch) incision is then made through the antimesenteric band into the lumen, and the mucosal lining is sutured to the skin using size 2-0 nonabsorbable suture in a simple-interrupted fashion. A stent bandage is applied over the colostomy for protection during anesthetic recovery.⁶⁷⁶

Alternatively, a diverting "loop" colostomy can be performed in the standing horse through a standard flank incision made 8 cm (3 inches) below the tuber coxae on the left side. The colon is formed into a loop, with both arms of the loop joined in a continuous Lembert pattern for 10 cm (4 inches), approximately 2 cm (0.75 inches) from the mesenteric attachment.⁹⁵³

A separate, 6- to 8-cm (2.5 to 3 inch) incision is made in the body wall on a level with the flank fold, parallel with the curvature of the costal arch and halfway between these points. The sutured loop of colon is then manipulated from the upper incision, through the lower incision, until it projects 4 cm (1.5 inches) above the skin surface. It may be necessary to transect muscle fibers and fascia to facilitate this step. As many simple-interrupted sutures as possible are preplaced to the deep layers of the body wall to attach the colon. The colon is then incised for approximately 6 cm (2.5 inches) along the antimesenteric tenia. The seromuscular edges are sutured to the subcutaneous fascia, and the mucosal edges are sutured to skin in a simple-interrupted fashion. The proximal edge of the stoma should open slightly cranial and ventral to the distal segment, and the lumen diameter should be preserved. If surgery is performed with the horse under general anesthesia, the above-mentioned procedure can be used or a single flank incision can be made in the ventral abdomen to accommodate the sutured-loop stoma. For the latter approach, the body wall incision is closed until it forms a snug fit around the colon in its ventral commissure.

The end-on colostomy can be performed through one or two incisions (Fig. 10-193).⁴⁵⁰ A routine paralumbar flank incision can be used for the initial manipulation and exploration of the abdomen. The lower flank incision is then used as the exit site for the cranial portion of the small colon. With an incomplete rectal tear without serious peritoneal contamination, the lower flank incision

alone can suffice for bowel manipulation. In either case the small colon is exteriorized in the lower flank region and prepared for surgical transection. The section of small colon to be used should be located several feet cranial to the rectal injury. This allows adequate mobilization of the small colon from its attachment, as well as the eventual and more technically difficult reattachment procedure. The caudal portion of the small colon is emptied of remaining ingesta with manual milking or by use of a tube passed forward from the rectum and past the tear until warm water can be safely flushed orally. The cranial segment is then oversewn or clamped, brought through the lower flank incision, and carefully pushed through the hole where it is firmly attached with a multiple-layer closure. It is very important that a circular incision only slightly smaller than the small colon diameter (7 to 10 cm [2.75 to 4 inches], average) be made through the skin, fascia, and fibrous layer of the external abdominal oblique muscle. Otherwise the stoma will not provide a large enough lumen for the safe and unrestricted passage of feces. Two techniques can be used to secure the cranial small colon segment to the body wall. One method is to fold back and suture the end of the small colon into a cuff so as to minimize the submucosal hemorrhage, which can persist for several hours after surgery.⁴⁵⁰ An alternative method is to exteriorize about 6 cm (2.5 inches) of the proximal small colon, so as to keep it away from the incision for the first day and make the deeper layers of suturing less likely to be contaminated. Careful meticulous closure techniques are necessary to prevent fecal contamination of the stoma site. A row of simple-interrupted sutures are used to attach the small colon serosa to the transverse abdominal muscle layer. A second layer of sutures, placed in a simple-interrupted pattern, attaches more of the small colon serosa to the internal abdominal oblique muscles. The small colon is further attached to the external abdominal oblique fibrous layer with size 0 absorbable suture material. The fascia and skin are sutured to the small colon mucosa with size 0 nonabsorbable suture in a simple-interrupted pattern.

Localized infection and subsequent abscessation can be avoided by careful attention to closure of all dead space, allowing for adequate size of the stoma and close postoperative attention to diet to avoid impaction at the surgical site. Other complications include peristomal herniation, prolapse of small colon, prolapse of small colon with rupture of mesenteric vessels, infarction, rupture of the colostomy, and spontaneous closure.^{945,971} More complications occur from stomal herniation and prolapse than from obstruction. As a result, the stoma and foramen should be made with greater concern for prolapse than obstruction.⁹⁴⁵ Although lush green pasture is adequate, water-soaked alfalfa pellets and frequent administration of mineral oil will ensure soft but formed feces.

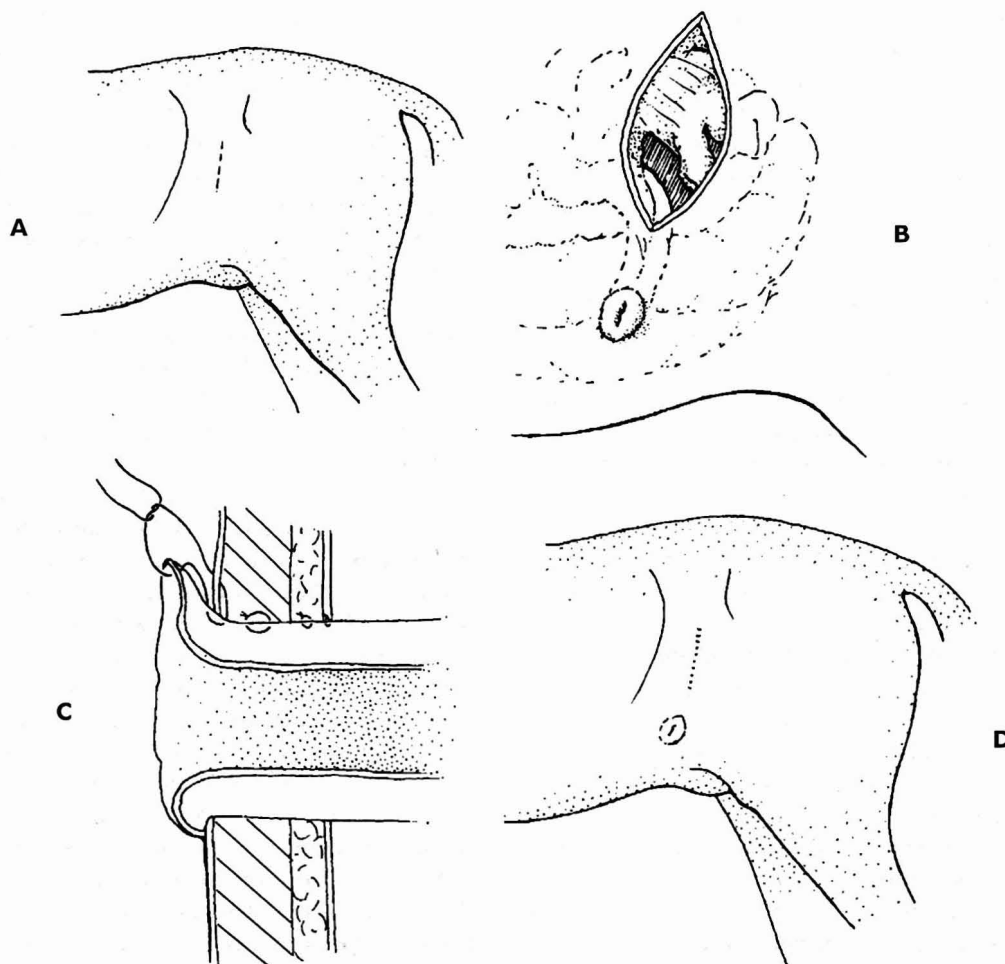


Fig. 10-193 End-on colostomy. **A**, A transverse flank incision can be used for the initial manipulation and exploration of the abdomen. **B**, After transection of the small colon, the proximal segment is oversewn and brought through the lower flank incision or a separate incision. **C**, Three rows of simple-interrupted sutures are used to firmly attach the small colon serosa to the transverse, internal, and external abdominal oblique muscles layers. The mucosa is sutured to the fascia and skin. **D**, The end-on colostomy is time-consuming to perform but does allow for the complete diversion of fecal material from the rectal tear.

Healing time varies from 4 to 6 weeks, and the tear should be rechecked by palpation as infrequently as possible (every 5 to 7 days) during that time to avoid risk of further damage. The colostomy site often becomes edematous within the first 24 hours after surgery. Careful administration of warm water enemas to keep the lumen open and prevent impaction and patient discomfort may be necessary. These horses should be maintained on broad-spectrum antibiotics (potassium penicillin G 44,000 IU/kg IV qid and gentamicin sulfate 4.4 mg/kg IV bid), an NSAID (flunixin meglumine 0.25 mg/kg IV or IM qid), and heparin 40 IU/kg IV or SC tid, which may aid in preventing adhesion formation.

Ileus is a common complication after repair of a rectal tear. Peritonitis from the tear and surgical manipulation

of the small colon, as well as postoperative anesthetic depression of bowel motility contribute to this complication. Although these concerns will subside with time, neostigmine can be administered early to prevent ileus and decrease patient morbidity and mortality.^{95a} It is generally administered intravenously via a slow-drip system at 2 mL/h (0.01 mg/kg/h) connected to the intravenous catheter. If the horse shows signs of discomfort, the rate of neostigmine administration can be decreased. Neostigmine administration is stopped in horses that continue to be in pain. The drip is used for 48 to 96 hours postoperatively to enhance propulsive activity of the large colon. Metoclopramide, which enhances gastroduodenal motor activity, may be used separately or in combination to prevent or treat ileus.³⁴⁶ Correcting all



electrolyte disturbances, walking the horse routinely, feeding a diet of lush green grass, administration of analgesics, and control of peritonitis all play equally critical roles in minimizing occurrence of ileus. Waiting for the bowel to become severely distended or for other metabolic problems to arise impairs the intestinal motility and jeopardizes survival of the patient.

A warm water enema to keep the lumen open and to prevent reimpaction may be necessary as the colostomy site becomes edematous within the first 24 hours after surgery. It is important to treat local abscesses as they arise at the stoma by drainage and lavage to allow the tissues to heal before the reanastomosis procedure. Serial peritoneal fluid analyses can be used to assess the abdominal response to the tear, and peritoneal lavage can be performed as an adjunct to control inflammation. Serious consideration should be given to the treatment of peritonitis if the patient is febrile, depressed, anorectic, or has ileus. Further evidence of peritonitis is indicated by increased quantities of peritoneal fluid with a nucleated cell count exceeding 150,000 cells/mm³, karyolysis of the neutrophils, or the presence of bacteria and a high total protein concentration in the fluid.^{955a,956} A large-bore (30 French) mushroom catheter may be inserted through the linea alba into the cranial abdomen and used to infuse 3 to 10 L of warmed lactated Ringer's solution into the abdomen. After an hour, the fluid is allowed to drain out the same catheter.

The method of closure for the loop colostomy involves taking down the stoma. The attachments to the skin and external abdominal oblique muscles are carefully dissected free from the edge of the small colon. The antimesenteric band is closed with double-inverting layers, using 2-0 absorbable suture, and the small colon is vigorously cleaned and replaced in the abdomen. If the small colon is excessively traumatized in this dissection, a short segment should be brought out of the incision and a resection and end-to-end anastomosis performed. The flank incision is then closed in a routine manner.

A ventral midline celiotomy is usually necessary for reanastomosis of the end-on colostomy. This approach allows for the adequate assessment and breakdown of adhesions from the rectal tear or colostomy and provides adequate room to manipulate the two small colon segments for the anastomosis and emptying of the large colon, should it be necessary. The stoma is prepared in an aseptic manner, and the small colon is packed with povidone iodine-soaked cotton. If the stoma has been complicated with an infection or abscess around it, the small colon should be transected and oversewn within the abdomen. The stoma and short segment of small colon are dealt with separately. This eliminates the possibility of peritoneal soilage from the abscess site. The proximal segment and distal segment are transected a few centime-

ters from their ends. An end-to-end hand-sewn anastomosis is performed with size 0 absorbable suture in an interrupted pattern, followed by a continuous Cushing pattern with size 2-0 absorbable suture. Routine closure of the mesentery and abdominal incision is then performed.

If present, the stoma and remaining short segment of small colon are then handled separately, with the horse rotated into lateral recumbency. The remaining segment is dissected free from the abdominal wall muscle and fascia and removed. The body wall edges are debrided and closed in a routine manner. A Penrose drain may be inserted between the fascia and the skin in the likely event of postsurgical seroma or sepsis.^{955a}

Loop colostomy may be of benefit to horses with rectal tears, provided it is done soon after the tear occurs. In two retrospective studies of 13 horses with grade 3 rectal tears, seven survived.^{953,961} Complications after loop colostomy include septic peritonitis, laminitis, incisional infections of the colostomy site, peristomal hernia, and prolapse. Complications associated with colostomy include stoma abscesses, prolapse, dehiscence, disuse atrophy of the distal portion of the small colon and intraabdominal adhesion formation.^{922,927,945,953}

Inflammatory, Infectious, and Immune Diseases

PERIRECTAL ABSCESS, STENOSIS, AND STRICTURE

Perirectal abscesses, rectal polyps, and strictures can narrow the lumen to the extent that passage of feces is impaired, causing impaction and colic.^{956,972,973} Perirectal abscesses most commonly develop secondary to rectal tears. Other causes include bruising of the rectal wall secondary to trauma from foaling and intramuscular injections in the gluteal region.⁹⁷³

Clinical Signs and Diagnosis

The most common clinical signs include low-grade abdominal pain, depression, anorexia, reduced fecal production, tenesmus, and possible fever. Additional diagnostic tests might include abdominal paracentesis, biopsy, aspiration, impression smears, and ultrasonography. *Streptococcus zooepidemicus* and *Escherichia coli* are the most common organisms isolated from abscesses in this region.⁹⁷³

Treatment

Treatment of perirectal abscess in the standing horse includes drainage and flushing of the abscess cavity after epidural anesthesia or sedation and local anesthesia. The surgical approach depends on the location and extent of the abscess. Abscesses located lateral to the anus are drained to the outside by an incision in the perineum



adjacent to the anus on the ipsilateral side. Dorsal abscesses are approached from and drained into the rectum, and ventral abscesses are approached from and drained into the vagina.⁹⁷³ Adjunctive therapy includes systemic antibiotic therapy consistent with the sensitivity pattern of the cultured microorganism, NSAIDs, flushing the wound with a dilute antiseptic solution, and administration of mineral oil and adjunctive stool softeners by nasogastric tube.^{956,973} Horses with abdominal abscesses involved must be treated for peritonitis; an exploratory celiotomy is required to treat the abscess appropriately.

The prognosis for resolution of perirectal abscesses is good if surgical drainage is effective and secondary complications do not occur. Peritonitis is a complicating factor for abscesses that involve abdominal organs. An exploratory celiotomy may be required to drain the intraabdominal abscess by marsupialization or to create a drainage tract into the rectum or vagina.^{945,974} Occasionally the resolved perirectal abscess can constrict and form a restrictive band around the rectum, resulting in blockage.⁹⁷¹

Strictures of the rectum that involve the rectal ampulla may require a diverting colostomy, because other treatments for this condition are unrewarding. Rectal strictures that involve the anus can be successfully treated only with transection of the anus and altering the diet to ensure that the feces are kept sufficiently soft that impactions do not occur.⁹⁷¹

PRURITUS ANI

Pinworms (*Oxyuris equi*) are the most common cause of persistent irritation to the anus and tail head. Hypersensitivity to *Culicoides* or learned vices may also result in constant rubbing of the tail head. In these instances irritation is not limited to the tail head. Persistent enteritis, diarrhea, or food allergy may also produce pruritus ani.⁹⁷¹ Pruritus ani can be successfully treated with appropriate anthelmintic treatment for pinworms (ivermectin 0.2 mg/kg PO or pyrantel 6.6 mg/kg PO), fly control, hyposensitization for *Culicoides*, and appropriate behavior modification for learned behavioral disorders.

Neoplasia

Squamous cell carcinoma and melanomas are the most common neoplasms of the anus and perineal region.⁹⁷⁵⁻⁹⁷⁷ Squamous cell carcinomas are locally invasive lesions that metastasize slowly. They are necrotic and foul smelling.⁹⁷⁷ Treatment includes surgical excision, cryosurgery, electrosurgery, laser surgery, hyperthermia, radiation therapy, immunotherapy, and combination of these methods.^{945,976}

Melanomas most commonly occur in the perineal region and the ventral surface of the tail in gray horses older than 15 years of age.⁹⁷⁶ They may be solitary or multiple, and diagnosis is made by clinical examination and biopsy. The lesions should be treated only if they are large enough to cause clinical problems. At this stage the lesions commonly metastasize and are associated with a poor prognosis. As a result, the treatment of choice is early wide excision or cryotherapy. Cimetidine, bacillus Calmette-Guerin (BCG), and radiation therapy have also been reported to be effective treatments.⁹⁷⁶

Although rare, intestinal leiomyomas or leiomyosarcoma are pedunculated masses that protrude into the bowel lumen or as mural masses. Metastasis of either type is rare.^{676,920,929,968} Digital palpation will help differentiate a mural growth from the more characteristic circumferential involvement of a prolapse or intussusception.⁹⁷² Removal of these masses involves appropriate circumferential mucosal and submucosal dissection and retraction of the mass with isolation and double-ligation of the vascular bundle.⁹⁷² Polyps of the rectal mucosa are usually pedunculated and are easily removed by ligation and division of the pedicle.^{907,945}

Lipomas of the mesorectum can occasionally cause strangulating obstruction of the rectum. If recognized early, they can be successfully treated by a colpotomy to resect the lipoma from its pedicle. Neoplasms, excessive fat deposits or other space-occupying lesions may fill the pelvic canal sufficiently to cause stricture or strangulation of the rectum.^{945,971}

Multifactorial Diseases

RECTAL PROLAPSE

Although rare, rectal prolapse can occur in horses of all ages. Any condition that results in prolonged tenesmus, such as parturition, dystocia, diarrhea, constipation, or rectal irritation can lead to prolapse of the rectum.* Prolapse of the bladder via a rectovaginal tear may resemble rectal prolapse.

Clinical Signs

Horses in poor general condition appear to be predisposed to the development of rectal prolapse.⁹³⁷ The mesocolon of the terminal small colon in the horse does not appear to be long enough to allow large portions of the terminal small colon to undergo intussusception and prolapse through the anus without tearing of the terminal mesocolon and possible disruption of the vascular supply.⁹⁷⁹ Abdominal paracentesis and cytology could establish prognostic information about the vascular integrity of the involved tissue.⁹⁷⁴

*References 676, 927, 930, 932, 937, 945, 974, 978.



Diagnosis

Four types of rectal prolapses have been categorized according to the specific tissues involved (Fig. 10-194). Type 1 rectal prolapses result from the caudal displacement of the rectal mucosa; rectal musculature and serosal tissues are not displaced. These tissues are usually edematous and appear most prominent along the ventral aspect of the rectum. With increased duration of the prolapse, the mucosa can become friable or necrotic. Type 2 prolapses generally involve displacement of the entire rectal wall, with occasional involvement of the rectal ampulla. Type 2 prolapses have a cauliflower appearance. Type 3 rectal prolapses involves displacement of the entire rectum, with invagination of the terminal small colon. The prolapse is firm and cylindrical. Type 4 prolapses are the result of the peritoneal rectum and a variable length of the small colon forming an intussusception through the anus.^{945,974,978} Type 3 or 4 rectal prolapses can result in infarction of the peritoneal rectum, if the mesocolon is torn or after mesocolic rupture in postparturient mares.^{930,979} Resection and anastomosis are usually impossible. Extensive disruption of the mesocolon and colonic vasculature make this form of rectal prolapse the most clinically severe. This type of prolapse can occur after dystocia in mares.^{907,978}

Treatment

Treatment of the inciting cause of the rectal prolapse is the most important aspect in the correction of the condition. Type 1 and 2 rectal prolapses usually respond to medical management. Manual reduction may be successful, and emollients or lubricants are applied to soften and soothe the prolapsed tissue. The topical administration of hyperosmotic compounds such as glycerin or 50% dextrose may be effective in reducing mucosal edema while lubricating prolapsed tissue in preparation for manual replacement. Epidural anesthesia should be administered to reduce straining and to facilitate manual correction. A purse-string suture using doubled umbilical tape (0.64 cm [0.25 inch]) can be placed with four wide bites in a loose purse-string fashion 1 to 2 cm (0.50 to 0.75 inch) lateral to the anus. The suture is placed so that the external anal sphincter can be dilated to a diameter of 4 to 6 cm (1.5 to 2.5 inches) to permit defecation. The purse-string suture should be applied so that it can be loosened if the horse shows evidence of straining or rectal impaction. The horse should not be fed for the first 12 to 24 hours after correction of the impaction. Mineral oil should be administered via nasogastric intubation. Feeding the horse a laxative diet, along with administration of warm water enemas for the next 10 days, will reduce straining and lessen the recurrence of the con-

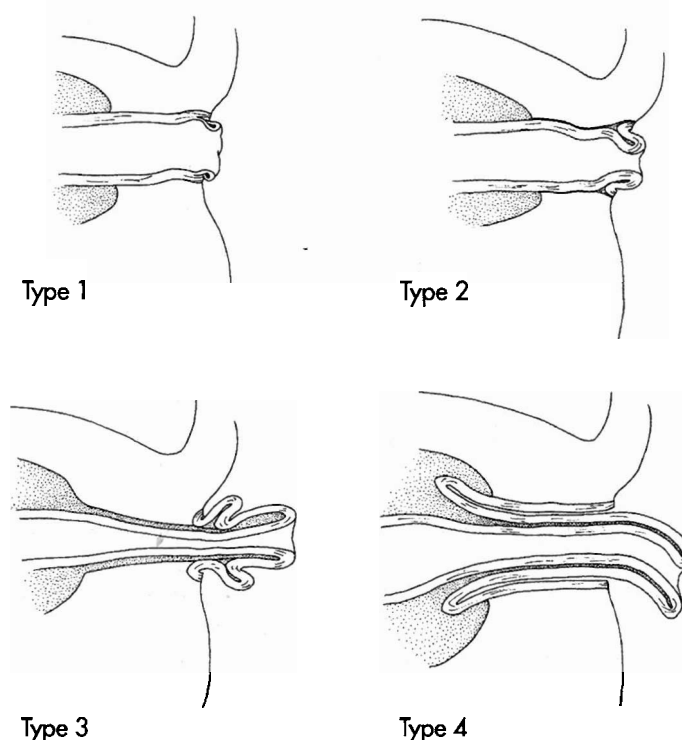


Fig. 10-194 Classification of rectal prolapse. **A**, Type 1: caudal displacement of the rectal mucosa. **B**, Type 2: displacement of the entire rectal wall with occasional involvement of the rectal ampulla. **C**, Type 3: displacement of the entire rectum with invagination of the terminal small colon. **D**, Type 4: prolapse of the peritoneal rectum and a variable length of the small colon forming an intussusception through the anus. Type 3 or 4 rectal prolapses can result in infarction of the peritoneal rectum if the mesocolon is torn or following mesocolic rupture in postparturient mares.

dition. The purse-string suture should be removed within 48 to 72 hours to minimize complications such as fecal retention.

Surgical intervention for type 1 or 2 rectal prolapses may become necessary if the prolapsed tissue becomes necrotic or medical management has failed. Submucosal resection can be performed after sedation, epidural anesthesia, and cleaning of the prolapse. Two 13.4- to 18.9-cm (6 to 8 inch), 18-gauge spinal needles placed at right angles through the external anal sphincter are used to transfix and expose the prolapsed bowel in position. Two circumferential and parallel mucosal incisions are made at the junction of the viable and nonviable tissue at the apex of the prolapse and the anus. These two circular incisions are joined by a longitudinal incision, and the tissue is removed by blunt and sharp scissor dissection in a plane between the mucosa and submucosa. Hemorrhage is controlled by direct pressure, ligation, or cautery. When all the prolapsed mucosa has been removed, the two mucosal edges can be easily brought together. The



mucosal edges are sutured together with a simple-interrupted pattern with size 0 or 1 chromic gut. The retention needles are removed, and the remaining portion of the rectum is reduced. Care should be taken to cover all denuded areas and prevent extensive granulation, scarring, and stricture formation.⁹⁷⁴ The prognosis for horses in which the prolapse is corrected by submucosal dissection is good. The affected tissues can be successfully resected, with no later recurrence of the prolapse.⁹⁷⁴

If the prolapsed rectal tissue is damaged beyond the mucosa, complete ablation of the prolapse may be required. The necrotic plaque is divided into quadrants with repeated resection and suture of one section at a time. Transfixation to a tube with long needles or pins and stay sutures facilitates the resection. Care should be taken to appose the muscularis, submucosal, and mucosal tissues accurately. Rectal strictures may develop if extensive areas of denuded rectal mucosa are allowed to heal by epithelialization and contraction. Pararectal abscesses are not a common problem. Obstipation, however, can be alleviated in the immediate postoperative period by nasogastric intubation of mineral oil and manual evacuation of the rectum.⁹⁷⁸

The distal small colon is prolapsed within the rectum in type 4 prolapses. These prolapsed tissues may be ischemic if the mesocolon and mesorectum are overstretched and torn as the small colon and rectum pro-

lapse. Treatment depends on the length of the intussusception, duration of the condition, value of the horse, and owner's wishes. If treatment is desired, the rectal prolapse should be evaluated by celiotomy to determine the most appropriate surgical therapy. Surgical attempts to amputate the rectum and terminal small colon by anastomosing the small colon to the anus are unlikely to be successful because of the likelihood of lost vascular integrity of the small colon and gangrenous necrosis at the anastomosis.^{974,979} If the involved segments cannot be resected entirely through a celiotomy, a colostomy should be performed.⁹⁴⁵ Affected horses require treatment for shock and endotoxemia.

RECTOVAGINAL TEAR AND FISTULA

Lesions between the rectum and vagina can range from a small perforation that is difficult to identify to a complete large communication between the rectum and vagina or a complete tear from the rectum and vagina through the perineum. These lesions occur as a complication of normal parturition or dystocia. Successful surgical repair hinges on reduction of the mare's fecal output, as well as maintenance of very soft feces before and after surgery. Repair is usually best postponed until the tissue trauma and edema have resolved and the local tissue architecture has become discernible.⁹²⁷ Rectovaginal tears are discussed in detail in Chapter 13, Reproductive System: The Mare.